

# Evolution of Radiotherapy with the Introduction of CT

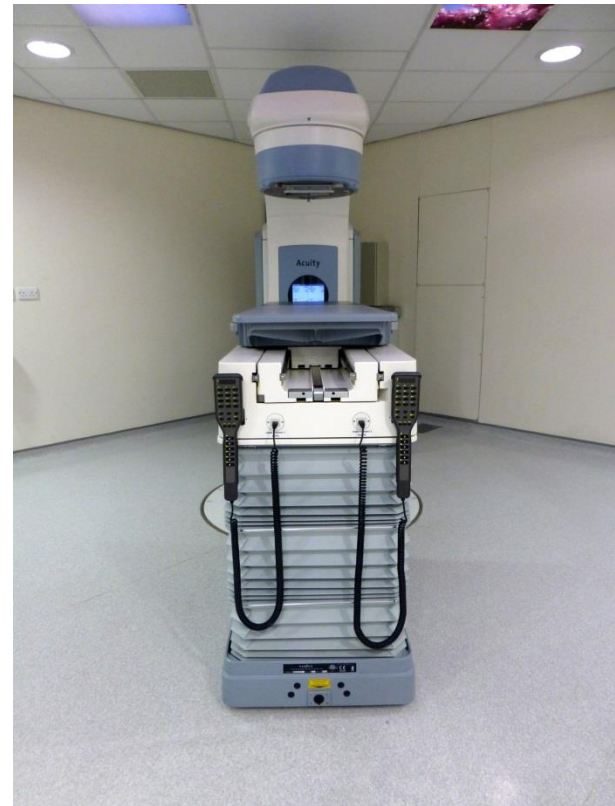Paula McLoone MSc BSc PGc

Macmillan Pre-Treatment Lead Therapeutic Radiographer

Castle Hill Hospital

# Past Planning Techniques <sup>1</sup>

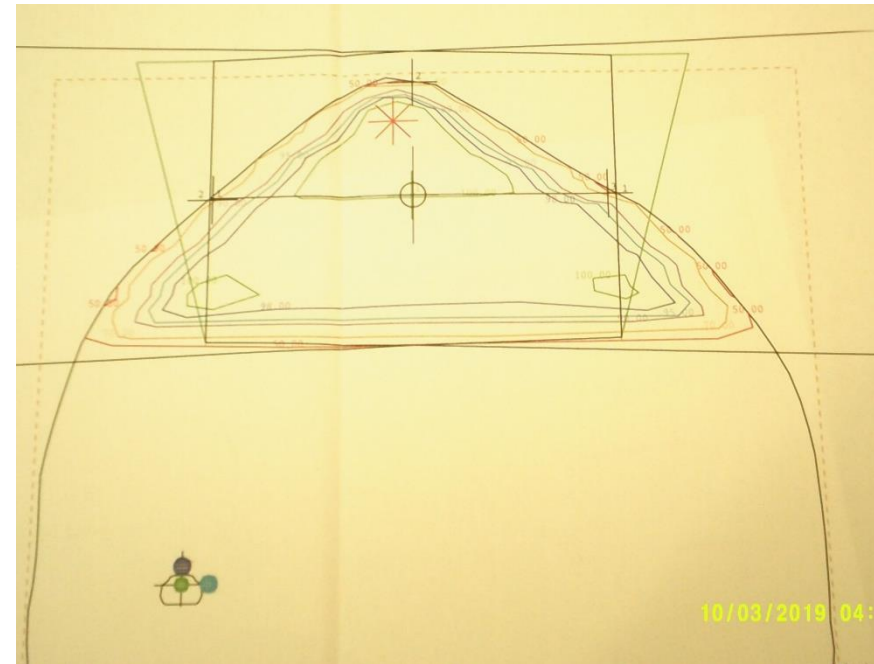

- Before the introduction of CT, radiotherapy planning was completed by acquiring kV images using a Simulator
- Further information was gained by taking measurements of the patient and making plaster of paris outlines of the area to be treated
- In some cases the area to be treated was decided on by the clinician and marked on without any imaging suffice the diagnostic images already taken



# Past Planning Techniques <sup>2</sup>

- Using these techniques allowed bone to be seen clearly but unfortunately soft tissue could not be visualised using these planning tools
- This meant the position of areas for treatment such as the prostate or cervix had to be approximated using bony anatomy for reference
- Due to approximation large margins for error had to be included increasing the area of irradiated tissue for treatment

# Past Planning



# Past Verification Techniques <sup>1</sup>

- As with planning, verification of the area to be treated used bony anatomy to confirm the treatment being delivered was correct
- In later years surgical clips could be visualised to aid with planning and verification but the clips could migrate leaving them as a guide not guarantee of position
- Both of these techniques worked on the assumption that soft tissue remained generally in the same area and the margin given to allow for movement was sufficient

# ALARA Principle

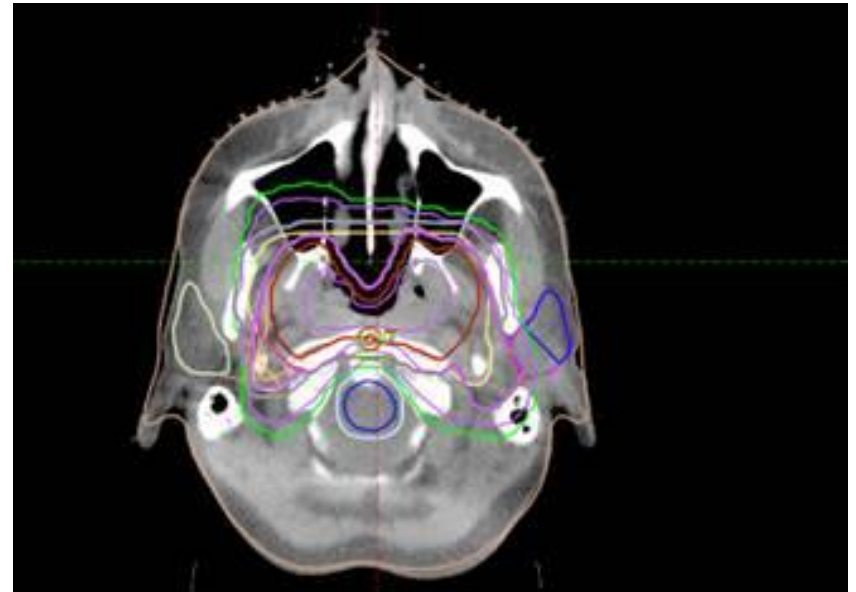
- Using kV images and the techniques for planning prior to CT planning we knew we were giving doses to areas that we did not need to but it was the only way to ensure we covered the area of cancer fully
- This extra area covered could lead to greater side effects but was justified in treating the disease in radical patients
- Utilising CT allowed radiotherapy to reduce the area to be covered with treatment and improve verification techniques bringing ALARA to the fore

# CT planning <sup>1</sup>

- Allows us to see the patients shape and internal anatomy over the full length of the treatment volume
- There can be accurate delineation of structures to be treated and also those to be avoided to decrease side effects or long term problems
- Allows us to accurately pin point the area to be treated and minimise the amount of healthy tissue to be included in the treatment volume
- Enables us to check the patient has followed guidelines for preparation for treatment

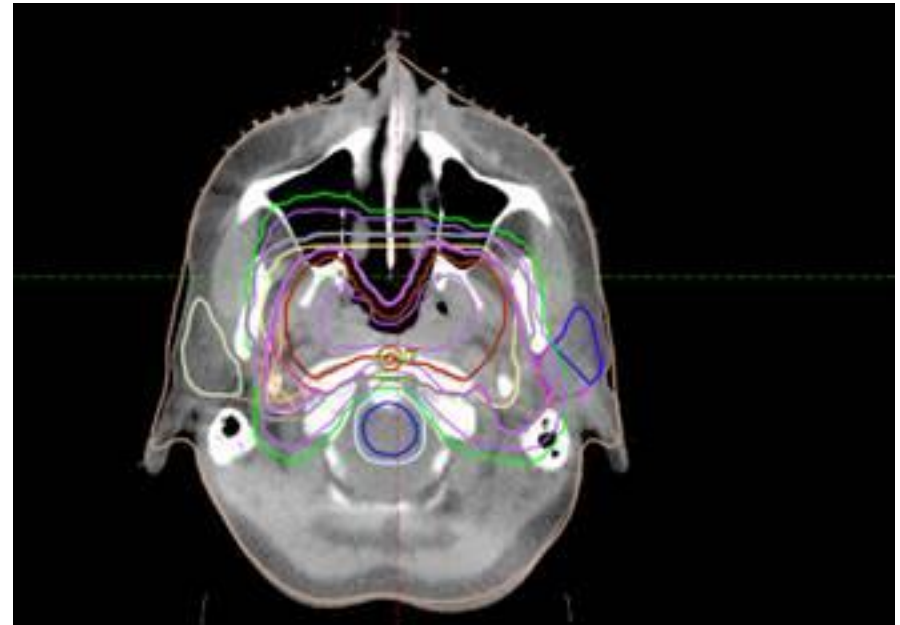
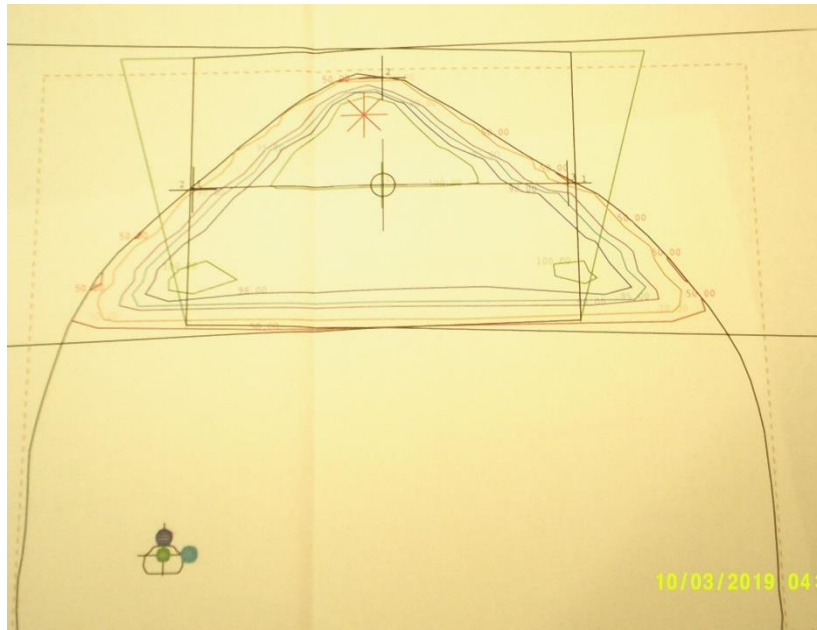
# CT planning <sub>2</sub>

- Can clearly see the tumour
- Organs at risk can be visualised
- Patient contour can be accurately delineated
- If any artificial joints were within the field they can be accounted for





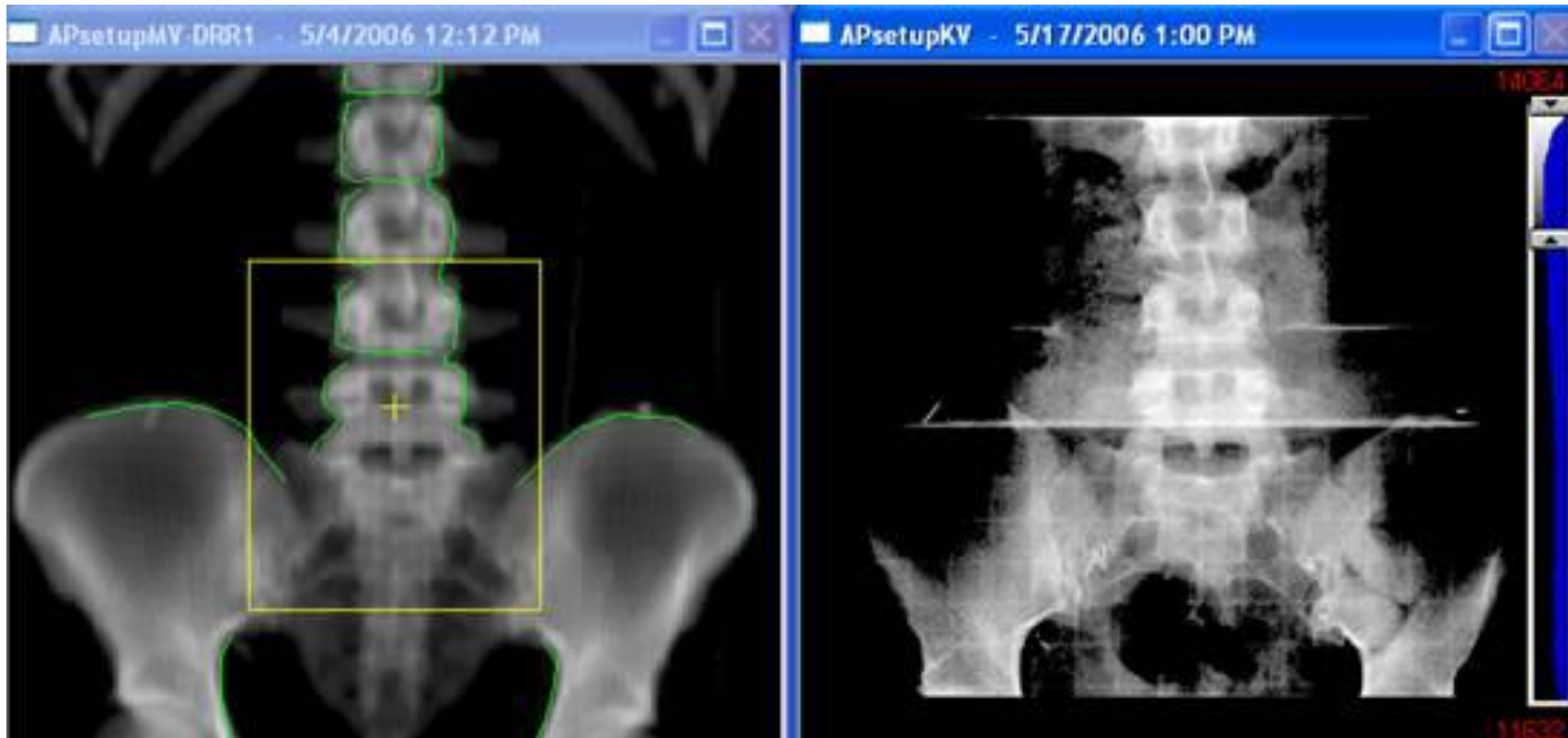# Comparing Old With New



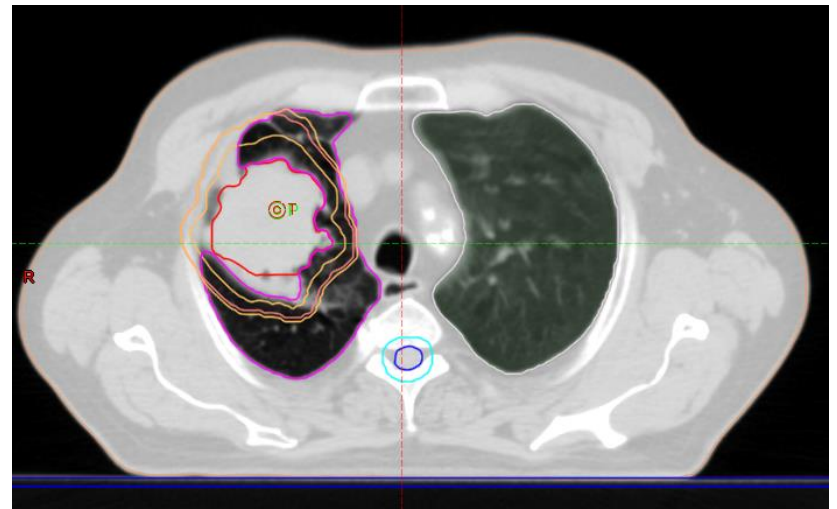
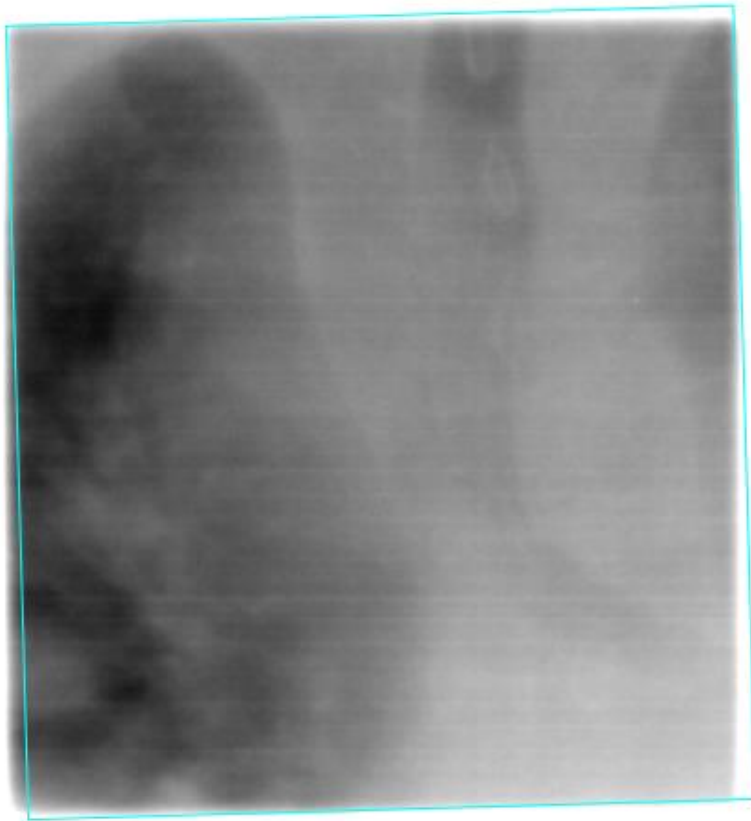
# Cone Beam CT Verification

- In the past Linear Accelerators could MV and kV image which gave us 2D images to match to, now however they can complete 3D imaging using cone beam CT
- This allows comparison directly between the original planning CT and the daily treatment CBCT of a patient ensuring the treatment planned is the treatment delivered
- It also allows us to see any changes in the patients situation such as weight gain/loss, tumour growth/ shrinkage & patient preparation allowing us to use adaptive radiotherapy to alter the treatment where required

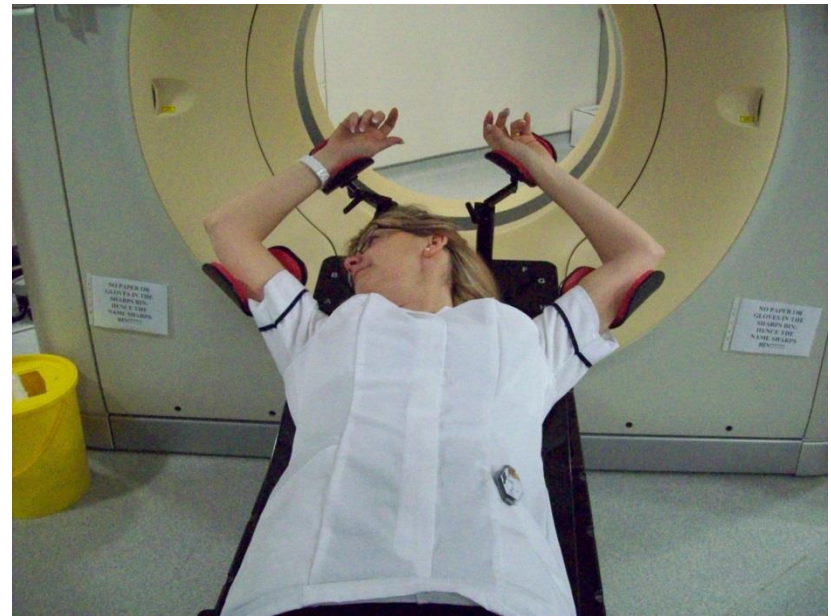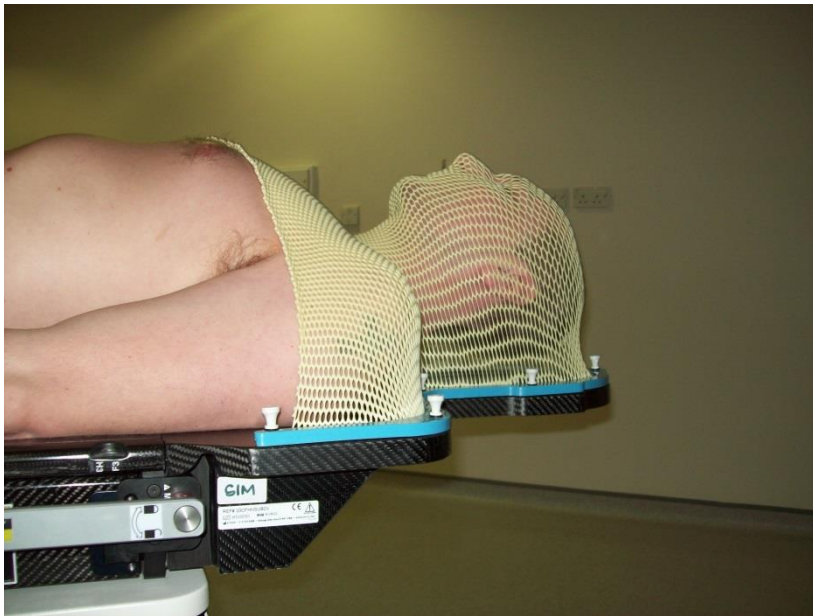
# Matching Before CT <sub>1</sub>



# Matching Before and After CT



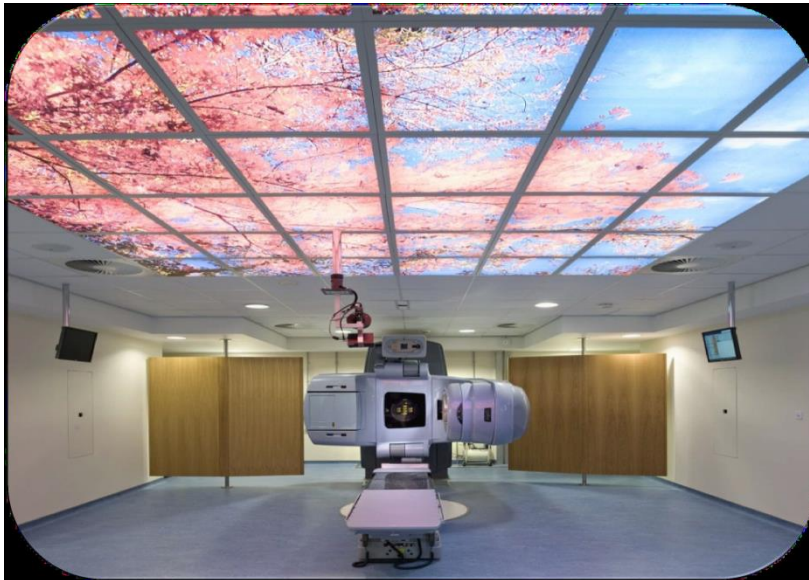# Why be precise in position if imaging is not?



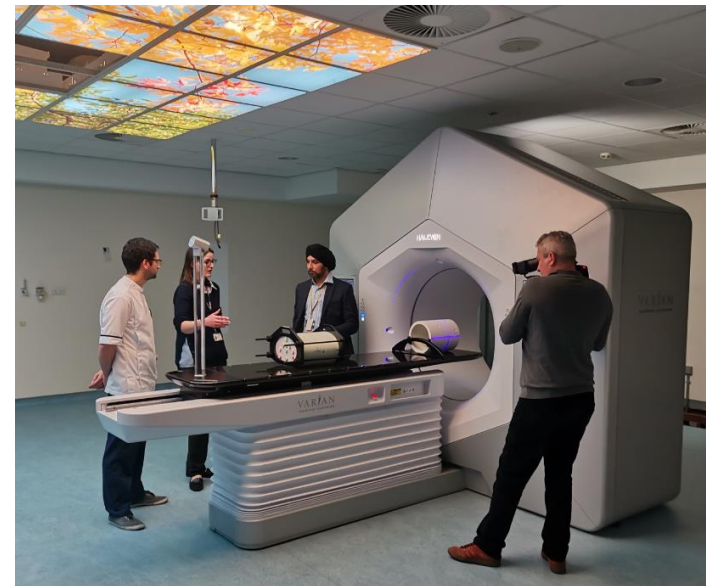

# Changes in Technology

**Linear accelerator**

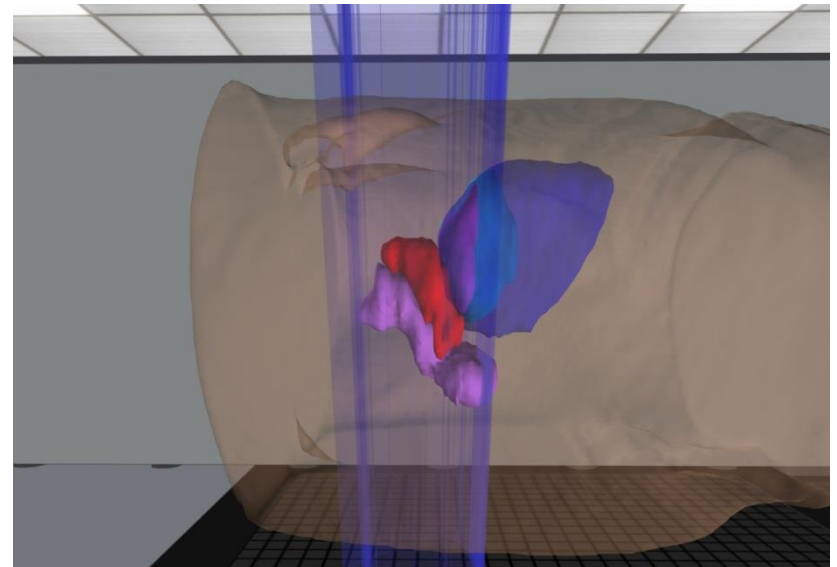


**Halcyon**



# Radical Pelvic Radiotherapy

- For these patients there are bladder and bowel requirements to ensure that each day the planned target volume is always within the treatment field
- A change in the fullness of bladder and bowels can change the amount of these structures that are in the treatment field thus increasing toxicity and side effects.




# Radical Lung

- Cancers to be treated in the head and neck and pelvis are relatively static where as those in the thorax and upper abdomen can move substantially due to breathing and diaphragmatic movement
- 4DCT gives us the opportunity to ensure the movement of the tumour is assessed at CT planning and the full motion of the tumour is covered in the planning process
- This can be recreated on treatment to start and stop the treatment beam to reduce the amount of healthy tissue being irradiated if tumours are found to move a lot whilst ensuring the tumour itself is fully covered.



# 4DCT Tumour Motion



# PEARL System <sup>1</sup>

- A computer programme that allows the patient to see the pathway they will be following, including-
  - The treatment machines
  - How they will be positioned
  - What immobilisation equipment we will be using
  - How the preparation such a filling / emptying their bladder, fasting etc affects the treatment plan
  - How the imaging arms look on a machine
  - How long the treatment will take

# PEARL System <sup>2</sup>

- Uses the information from the scans to show patients the importance of positioning and also the importance of the pre-scan / treatment preparation they are being asked to follow
- Clearly shows the difference in full and empty bladder and how this can change the treatment volume
- Also empty stomach verses full and how dramatically this can change the size of a treatment field and therefore the irradiated area
- Can calm nervous patients prior to scanning / treatment as they can see what is going to be happening throughout their treatment journey

# Summary

- CT has allowed radiotherapy to become more accurate in its planning and treatment
- CT has allowed for a reduction in unnecessary dose to anatomy that does not need inclusion in treatment fields
- Allowed for accurate image verification on treatment machines

# What about the future-PET

- Currently we utilise PET images to aid treatment planning
- We are trying to reduce the number of radiation interventions and as such are looking to set patients up in the treatment position and give them their treatment tattoos at PET which also reduces their number of visits to the hospital
- PET scans enable us to use tracer activity to ensure we are encompassing everything that requires treatment extremely useful for SABR patients whose lung tumours are so small they are extremely difficult to visualise

# What about the future - MRI

- Where we cannot clearly identify some structures patient have both a CT planning scan and MRI
- Recent advances in CT have reduced this work load as Metal Artefact Reduction technology also us to see structures that would usually have been “blackened out “ due to the metal hips themselves
- However MRI gives the option of planning with no dose implications and clear soft tissue delineation but at the moment the planning software is still catching up to allow full utilisation of this type of planning.
- Access to MRI scanners is also an issue due to the increase in demand for this imaging modality

Any Questions?