



PHILIPS

FieldStrength
MRI articles



MRI enters emergency department for fast, confident decisions

FieldStrength MRI magazine

User experiences – November 2016

www.philips.com/fieldstrength

When MRI is the preferred choice, ED patients can get fast MRI and fast diagnosis

When neurological emergencies require diagnostic imaging, common practice in the ED has been to perform CT rather than MRI, even when MRI could potentially produce more informative diagnostic images of spinal cord damage, disc protrusions, soft tissue injuries, and stroke pre-cursors. [1,2] The main reason is that timing is essential in emergency cases, and CT is generally faster than MRI. The St. Joseph's Hospital and Medical Center is now challenging this paradigm by offering rapid MRI scans within its Neurologic ED and seeing that it helps them make a richer diagnosis. A finding that supports our first time right philosophy.

“MRI is a better test for identifying soft tissue abnormalities in the brain.”



John Karis, MD

John Karis, MD, is a neuroradiologist and director of MRI and brain imaging at Barrow Neurological Institute at St. Joseph's Hospital & Medical Center in Phoenix, Arizona since the early 2000's. Dr. Karis completed his residency at the Duke University School of Medicine.

Introducing MRI in the ED: why the change?

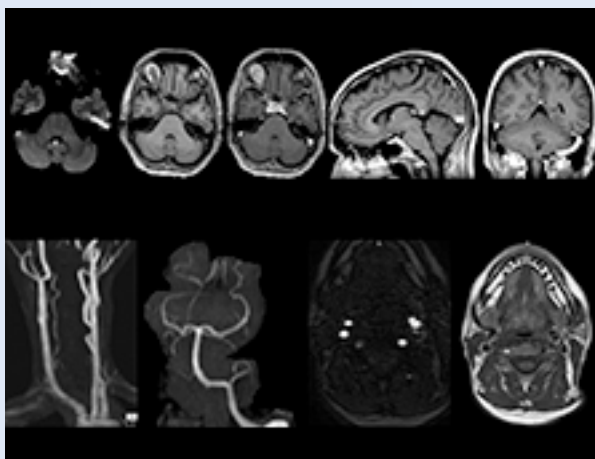
Since 2012, St. Joseph's Hospital and Medical Center in Phoenix, Arizona, USA, has had an ED dedicated to neurological patients. In 2015, John Karis, MD, of the Barrow Neurological Institute at St Joseph's spearheaded a project to place an MRI system in the Neuro ED. He stressed the added prognostic value of having an emergency MRI, and the importance of reducing radiation doses, particularly in patients for whom a CT scan was not the optimal test.

"In the past, CT scans were performed because of their availability and rapid turnaround time" Dr. Karis argues, "but if an MRI could

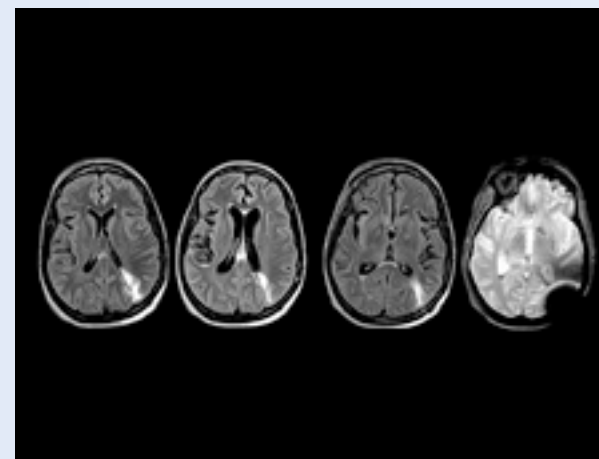
be as efficient as CT for referring physicians, then physicians would probably prefer MRI over CT in part of the cases. Reducing the number of CT scans for patients less than 40 years of age without significant acute findings, such as acute stroke, was also a main reason for introducing MRI into the ED.

"MRI is a better test for identifying soft tissue abnormalities in the brain. What really influenced the decision on the administrative side, was the total radiation dose received by ED patients, and how this could be reduced by introducing MRI in the ED".

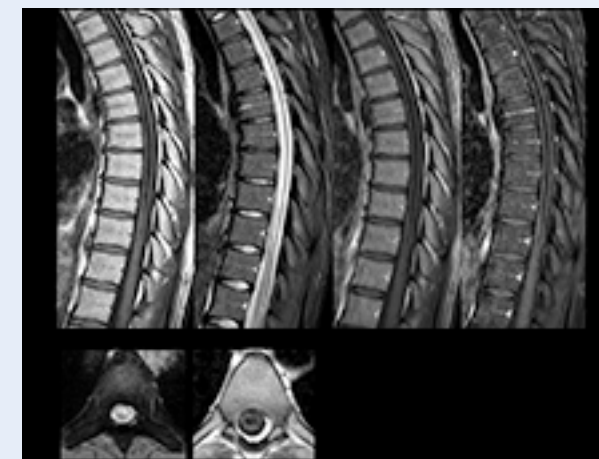Clinical cases



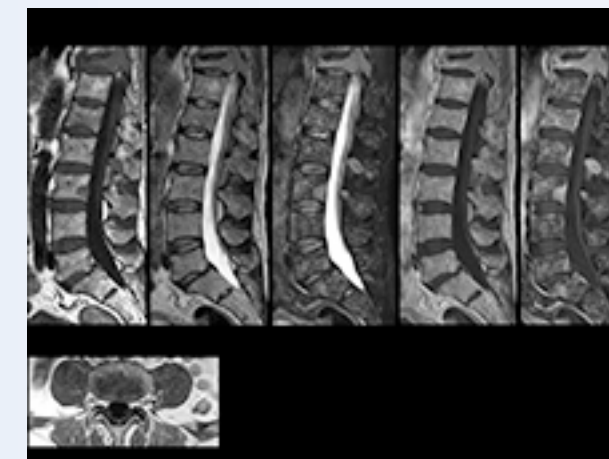MR angiography of head/neck



MRI helps uncover signs of meningeal carcinomatosis



Myelopathy imaging: the role of mDIXON



MRI helps reveal sources of back pain

Towards routine scan times of about 10 minutes

In order to address efficiency, matched with state-of-the-art capabilities to support a rich diagnosis, the decision was taken to include a Philips Ingenia 1.5T MRI scanner with wide bore in the new setup of the ED to enable scanning of virtually all patients.

To minimize the time taken to perform scans, rapid MRI examination protocols (ExamCards) were developed, shortening the total scanning time to even less than 10 minutes in some exams. Techniques like mDIXON (modified DIXON) are used for robust capturing of fat-free MRI images in a hectic ED environment.

“mDIXON is robust with regard to susceptibility type of problems that would come up with traditional spectral fat-saturated images.”



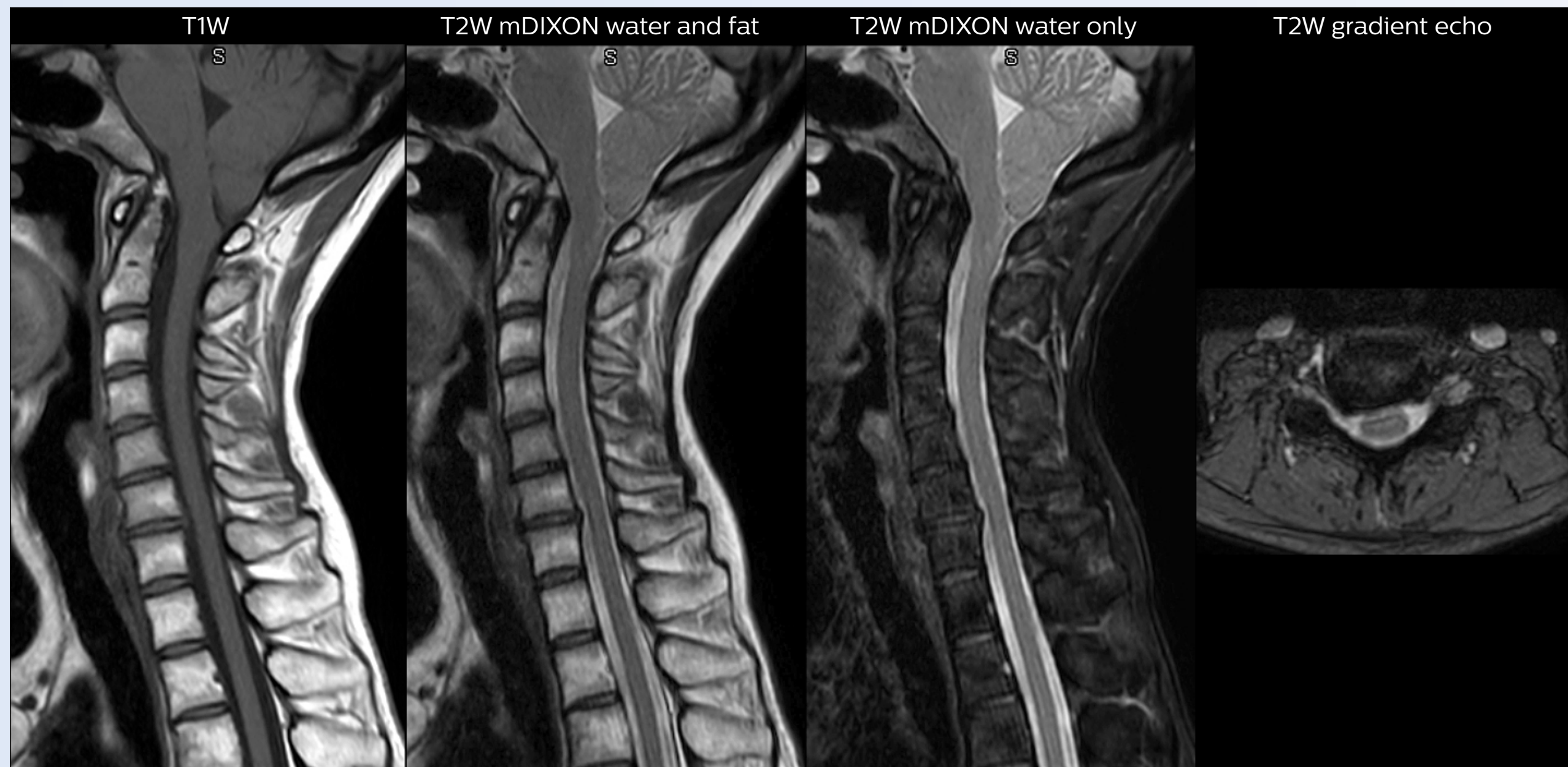
The Barrow Neuroscience Tower at St. Joseph's was opened in 2006.

“In our ED environment it’s really nice to have the fat-free imaging that goes along with the mDIXON technique.”

Including mDIXON TSE for robust fat suppression

“We use mDIXON TSE extensively in our spine imaging in the emergency room,” says Dr. Karis. “It’s particularly nice in that it is very robust with regard to susceptibility type of problems that would come up with traditional spectral fat-saturated images; these problems are essentially eliminated with the mDIXON technique. In our ED environment it’s really nice to have the fat-free imaging that goes along with the mDIXON technique.

“For the thoracic and cervical spine routine non-contrast exam, for example, we perform one mDIXON T2 TSE sequence, which provides us with two outputs: the fat-and-water-together T2-weighted images, as well as the water-only sagittal T2-weighted images. And then we also perform an axial gradient echo exam.”



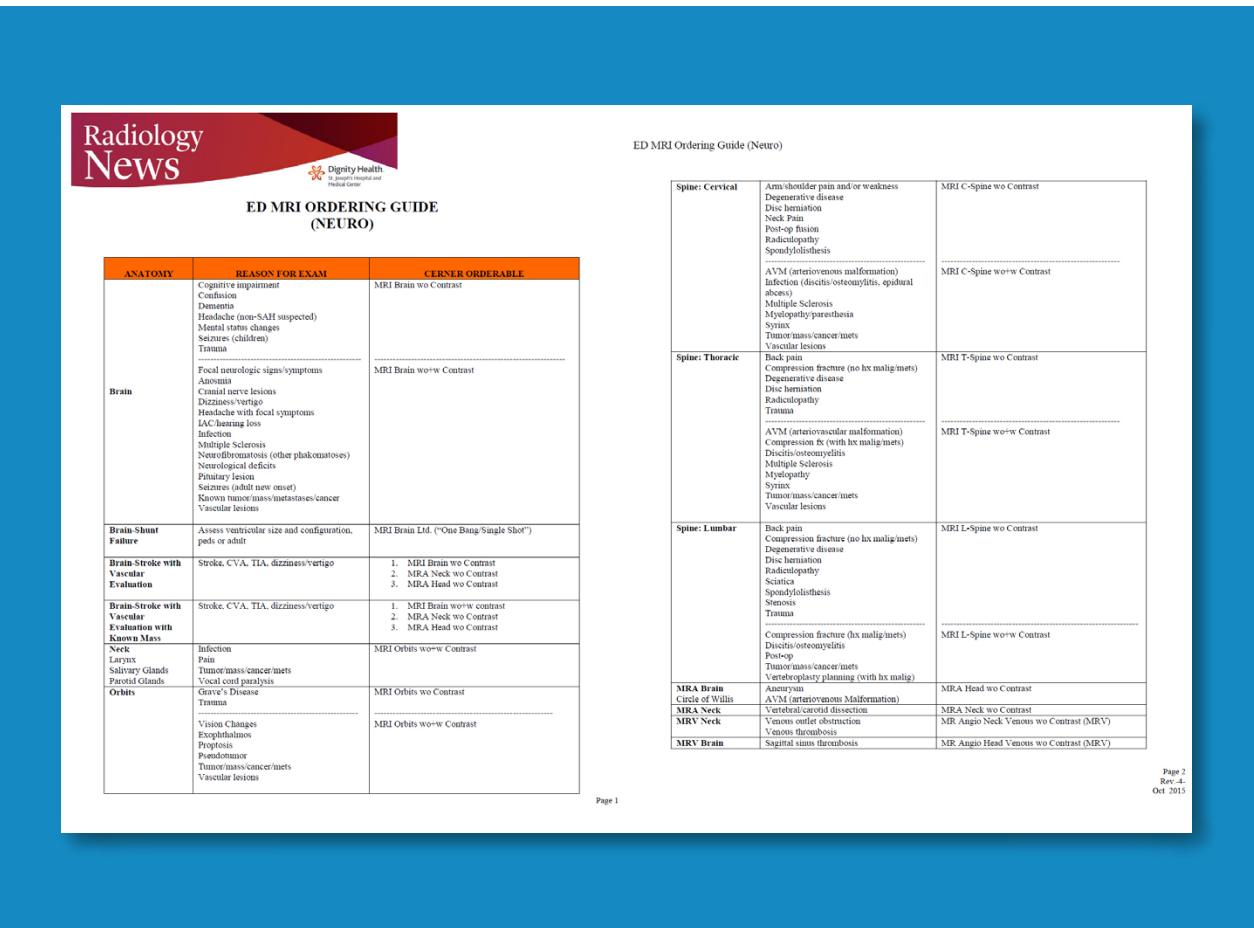
Cervical spine routine exam

This patient presented with headache that was worse with neck flexion and we see a Chiari 1 malformation with low-lying cerebellar tonsils as well as some degenerative cervical thrombolytic change.

Guidance on appropriate use of MRI

A range of protocol sheets was developed to help ensure that referring physicians order the most appropriate MRI exam. The optimized MRI protocols also include 3D contrast-enhanced imaging, allowing neurosurgeons to comfortably use the isotropic data in the operating room while performing stereotaxic surgery.

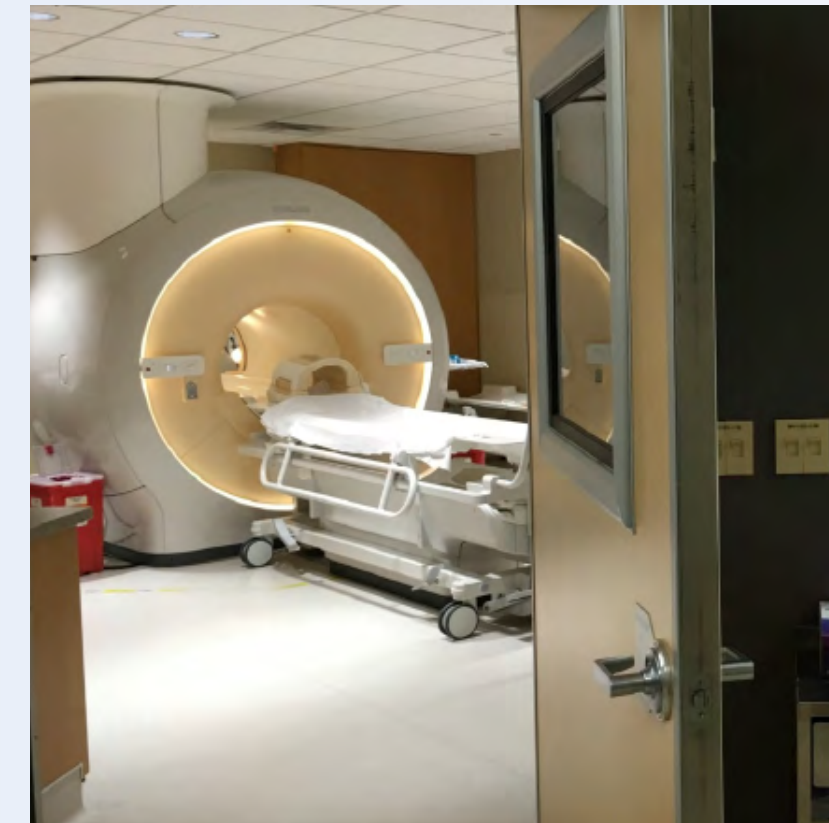
After the MRI scanning, the preliminary reports are made available to referring physicians more quickly than before, because that is what physicians need to make their decision on what to do with patient. Using a redesigned reporting process results in total turnaround times that are similar to those of CT. Another of the changes introduced is that MRI safety screening data are retrieved from the hospital information system, saving approximately 30 minutes.



[Download the ED MRI ordering guide of SJHMC](#)

Ingenia 1.5T MRI protocols for Neuro ED scans

Examination	Protocols				
Brain non-contrast	Sagittal T1	Axial DWI	FLAIR	T2 gradient echo	8:36 min. 26% of exams
Brain pre- and post-contrast	Sagittal T1	Axial DWI	FLAIR	-/+ 3D T1	13:59 min. 13% of exams
C/T-spine non-contrast	Sagittal T1	T2 mDIXON	Axial T2 gradient echo		9.3% of scans
C/T-spine pre- and post-contrast	Sagittal T1	STIR	+Gd sag/ax	T1 mDIXON	20:56 min. 5.3% of exams
L-spine non-contrast	Sagittal T1	T2 mDIXON	Axial T2 TSE	Cor T1	11:13 min. 9% of exams
L-spine pre- and post-contrast	Sagittal T1	T2 mDIXON	Axial T2 TSE	+Gd sag/ax	4% of exams
Head MRV	3D Phase Contrast				1.8% of exams
Head/neck MRA	2D TOF neck	3D TOF head			0.9% of exams



The MRI suite with Ingenia 1.5T

“The MRI scanner is available for targeted exams only. This requires referrers to think clearly about what they want to test.”

Changing established behaviors

The transition away from a predominantly CT-based ED began by educating physicians about the advantages of MRI in the emergency setting, when to use MRI, and the importance of targeted exams instead of broader, non-targeted exams.

Some resistance to the change was anticipated, as it was disrupting established routines, so a reasonable amount of time was planned for educating referrers, neuroradiologists and neurosurgeons, as well as residents and fellows. However, less time than anticipated was needed: all involved were already familiar with MRI and, more importantly, they were easily persuaded on learning about the 10-minute exam duration with MRI.

“We bring forward that the MRI exam time is similar to CT, which is very important to them”, says Dr. Karis. “One of the other points to stress is that the MRI scanner is available for targeted exams only. This requires referrers to think clearly about what they want to test. There must be a true commitment to the shorter time frame; otherwise, the process won’t work.”

“Experienced neuroradiologists adapted fairly instantly – they knew the value of MRI and as such, quite quickly learned to use just the three or four sequences for their diagnosis. In fact, one came to me and asked ‘why don’t we do this for all of our patients, all the time?’ This is not realistic in our center, of course [e.g. because of issues relating to demand, availability, and the range of conditions dealt with] but it illustrates the confidence in the approach”.

“In my experience a negative MRI, because it is so sensitive to abnormality, far exceeds the value of a negative CT.”

The high value of a negative MRI scan

“One of the most important decisions an ED physician has to make is to admit or discharge their patient. So a physician who is better informed by an MRI exam can make this decision with more confidence. By converting to a test that has a far better potential to identify issues, physicians get a better and more certain diagnosis.”

“In my experience a negative MRI, because it is so sensitive to abnormality, far exceeds the value of a negative CT. A negative MRI can allow physicians to be more confident about making discharge decisions, potentially reducing the number of admissions in cases of doubt, and offering cost savings for the institute.”

“There are far more decisions being made to send people home than to admit. And in terms of making that decision, I believe there’s no more valuable exam than a negative MRI for neurologic disorders.”

“The only unforeseen challenge,” says Dr. Karis “was the tendency to still perform non-targeted exams, particularly among less experienced staff and new neurology or neurosurgery residents. Since MRI image quality is so excellent, it’s just easier to ask for a number of tests, and then your exam goes from in and out in 10 minutes to much longer.”

Education – implementation – results

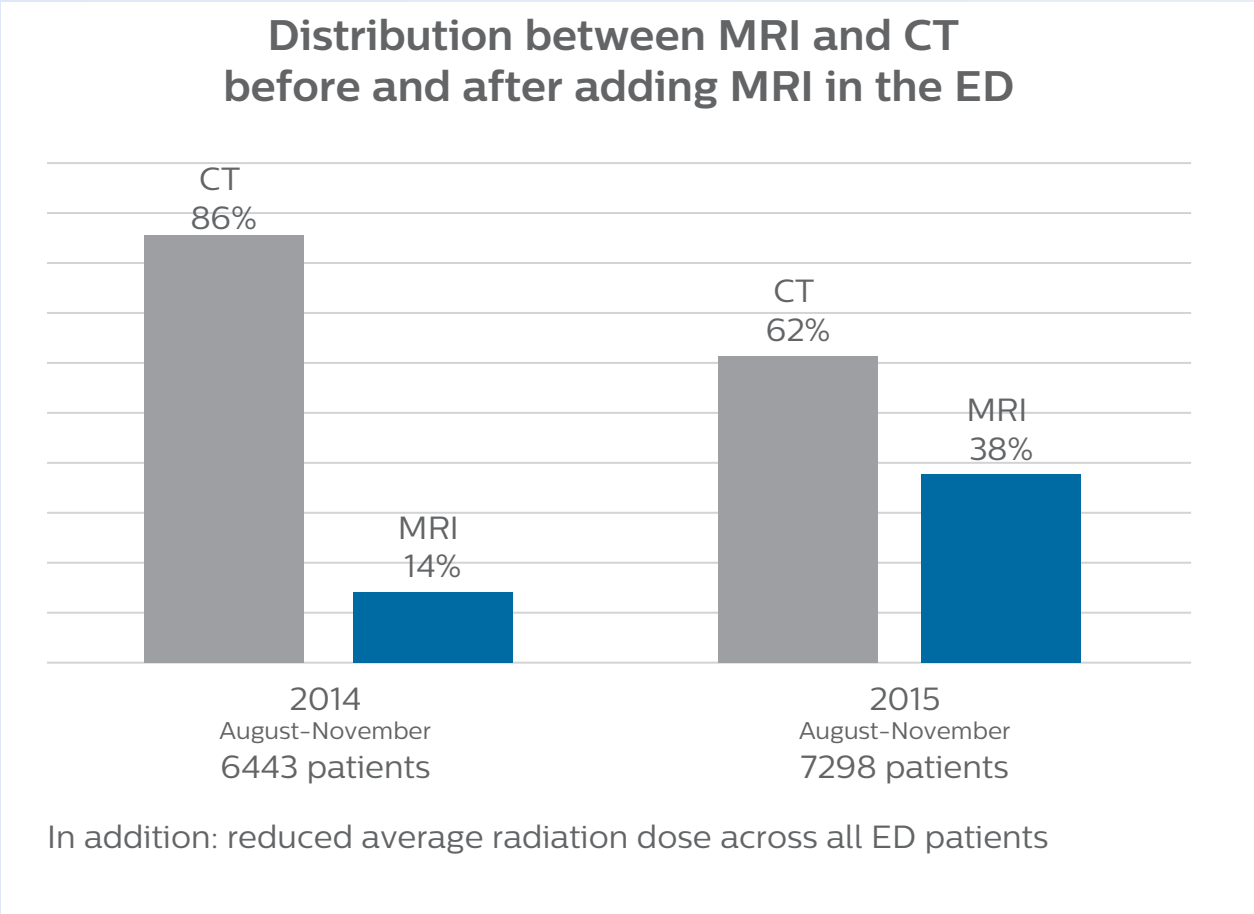
The ED physicians can only request exams from a selected set of available exam protocols – as represented on the protocol sheet – minimizing the time necessary for the MRI scan. The sheet contains advice as to which scan to order (i.e. MRI vs. CT, contrast vs. non-contrast) depending on the situation, and encouraging physicians to order targeted scans.

Even though the process has now been implemented, education still remains important; new neurology residents, for example, are informed as to the use of the ED MRI scanner, how it’s being utilized, and the importance of targeted scanning.

“In my opinion, education has been crucial to establish the MRI exam as an ED test,” says Dr. Karis. “This is really key. If you can’t establish this concept, then you can’t convert everyone to the mindset that this is an ED test.”

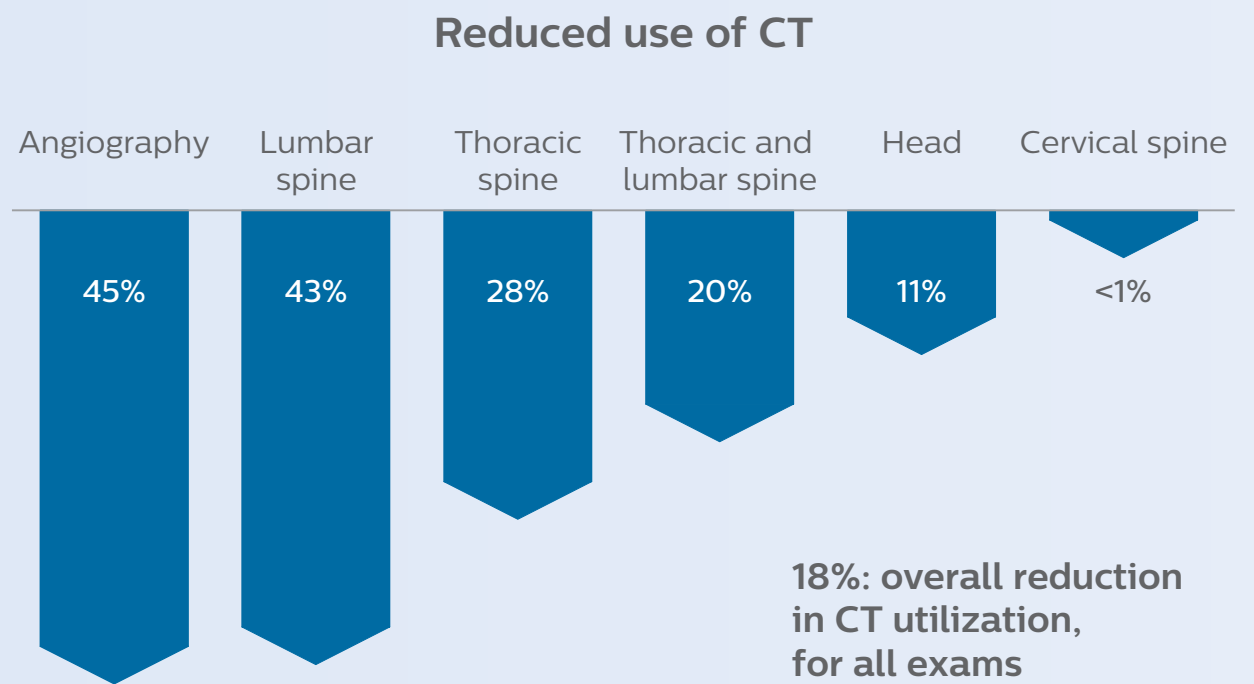
“In my opinion, education has been crucial to establish the MRI exam as an ED test.”

Growth of MRI in the Neuro Emergency Department



“Our results show that a dedicated MRI in the ED can be effectively implemented; patient turnaround times with MRI were on par with CT. Interestingly, even though the MRI exam protocols were shortened, this robust yet rapid scanning still yielded good quality images, further improving our workflow and almost eliminating the need for repeat scans or follow-up scans.” says Dr. Karis,

“Before, when patients received CT in the ED, it was quite common that they would need an MRI afterwards. However, in the four months that I have logged data for this study, I have not become aware of a single patient that underwent MRI in the ED and had to come back for repeat imaging, probably because the protocols are so robust. Patients with complicated cases requiring specialty acquisition types are the most common reason for recalls at our institution.”



“In the four months that I have logged data for this study, I have not become aware of a single patient that underwent MRI in ED and had to come back for repeat imaging.”

Throughput and financials of MRI in ED
St. Joseph’s Hospital and Medical Center

Throughput	Financials
<p>1199 MR examinations in August 2016</p> <p>39 patients/day on average</p> <p>Highest day: 62 exams in 24 hours</p>	<p>All exams reimbursable</p> <p>\$453.71 average hospital reimbursement per exam, which equates to</p> <p>\$554,000 MR revenue for August 2016.</p> <p>>1.5 million coded reimbursement over 3 months (June – August 2016) This reimbursement does not include the technical fee the radiologists get on top of the hospital coded reimbursement.</p>
Scanner operation	
<p>7 days a week</p> <p>99.2% uptime (June–August 2016)</p>	

How to achieve a successful transition?

The successful incorporation of MRI into the ED is dependent on several factors, according to Dr. Karis.

“First, it is necessary to have the MRI in close proximity to the ED, bypassing the need for hospital staff to leave the ED for extended periods in order to accompany patients to other departments. Also, exams must be streamlined, so that they can be performed in about 10 minutes or less. Targeted scans should be ordered for the specific issue at hand, and non-targeted exams should be

discouraged. In particular, neurology and neurosurgery residents who work overnight shifts should understand the shortened protocols, in the effort to avoid ordering extra scans that could extend exam times and hinder workflow.”

Dr. Karis recommends that a global view should be considered before the change can be implemented. “You need to look at everything, from metal screening and nursing, to transport and proximity to the ED, if you’re really going to make this transition successfully.”

“You need to look at everything, from metal screening and nursing, to transport and proximity to the ED, if you’re really going to make this transition successfully.”

Future plans: expansion to stroke and TIA patients

At St. Joseph’s Hospital and Medical Center, the dedicated MRI system in the ED has been shown to efficiently provide high quality MR images that assist physicians in making informed decisions on patient diagnoses and take a more definitive decision on follow-up. The decision to have a dedicated ED MRI has resulted in rapid patient turnaround, efficient patient management, and substantial reductions in radiation dose.

For Dr. Karis, the next goals for the neuro ED include converting the exams for acute stroke and TIA patients from CT to MRI, offering an alternative management option for these patients. Also, collaboration between other departments is currently underway, encouraging the performance of targeted exams with the ED MRI. These improvements in workflow and faster turnaround times may result in further reductions in scanning time.

References

1. Singh R, Kumar RR, Setia N, Magu S. *A prospective study of neurological outcome in relation to findings of imaging modalities in acute spinal cord injury.*

Asian J Neurosurg. 2015;10:181–9.

2. Grimm JM, Schindler A, Schwarz F, Cyran CC, Bayer-Karpinska A, Freilinger T, Yuan C, Linn J, Trelles M, Reiser MF, Nikolaou K, Saam T. *Computed tomography angiography vs 3 T black-blood cardiovascular magnetic resonance for identification of symptomatic carotid plaques.* J Cardiovasc Magn Reson. 2014;16:84.

Clinical cases

View clinical case: MR angiography of head/neck

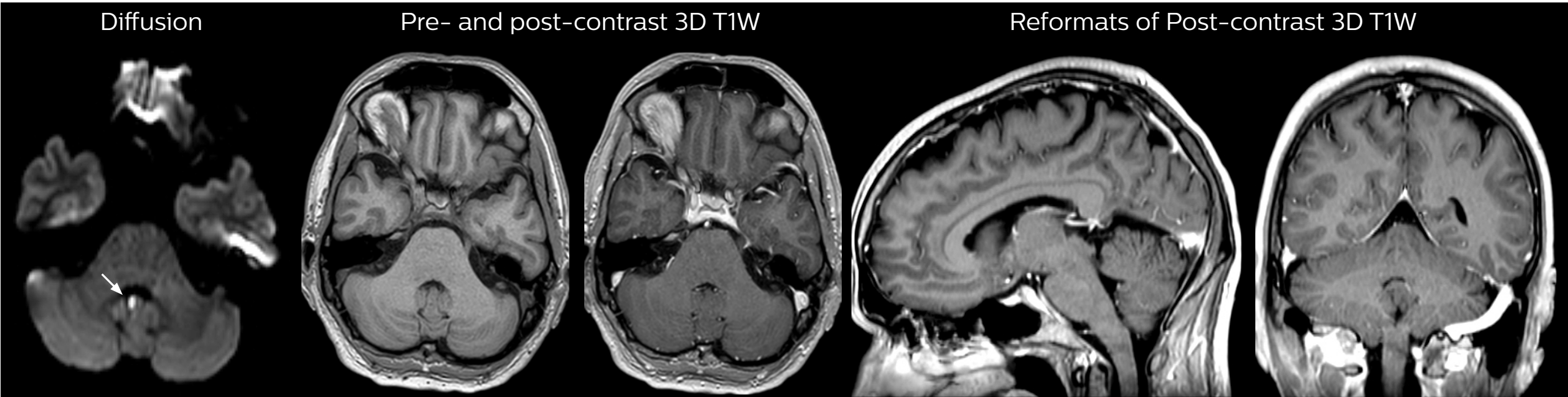


MR angiography of head/neck

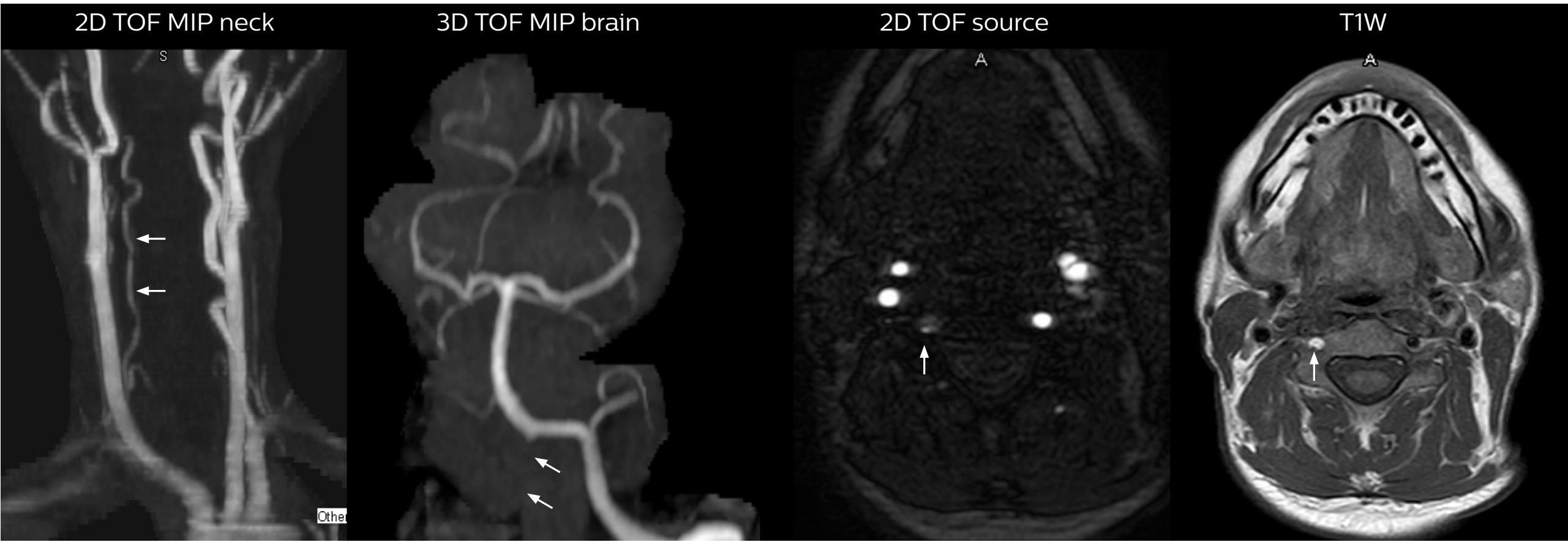
This patient with complaints of transient weakness presented at the ED. Pre- and post-contrast MRI on Ingenia 1.5T showed unremarkable results, except for one small diffusion abnormality focus in the posterior fossa, which was concerning for acute stroke, but there were no additional findings in the pre- and post 3D T1W or the sagittal and coronal reformats. So, additional MR angiography of the head/neck was recommended.

A small right vertebral artery with only minimal flow is visualized on the 2D TOF image that is highly sensitive to flow and there is non-visualization of flow within the distal vertebral artery on the 3D TOF image. The axial source images of the neck show dissection of the right vertebral artery, with small residual lumen and reduced flow.

Pre- and post-contrast brain exam



MR angiography of head/neck.

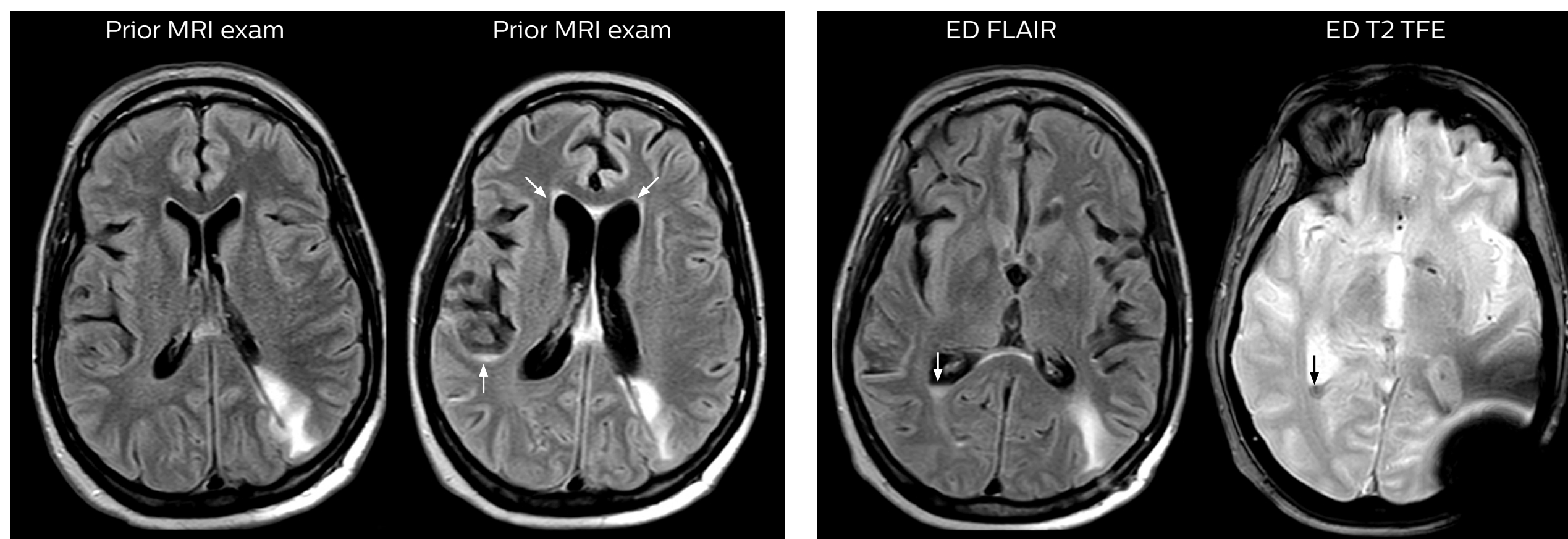


MRI helps uncover signs of meningeal carcinomatosis

A patient with previously resected metastatic focus from the posterior fossa, presented to the ED with new symptoms of meningismus and headache. The MRI exam done in the ED is compared to images from a previous standard, longer time, clinical MRI study with a higher resolution. The ED image shows interval increases in ventricular size and a new abnormal signal within the subarachnoid spaces (arrows), indicative of an underlying process that is either infectious or hemorrhagic. In this patient it turned out to be related to meningeal carcinomatosis.

The axial T2 gradient echo image shows a component of blood layering in the trigone of the right lateral ventricle. The FLAIR image also shows the layering as well as abnormal signal in the subarachnoid spaces.

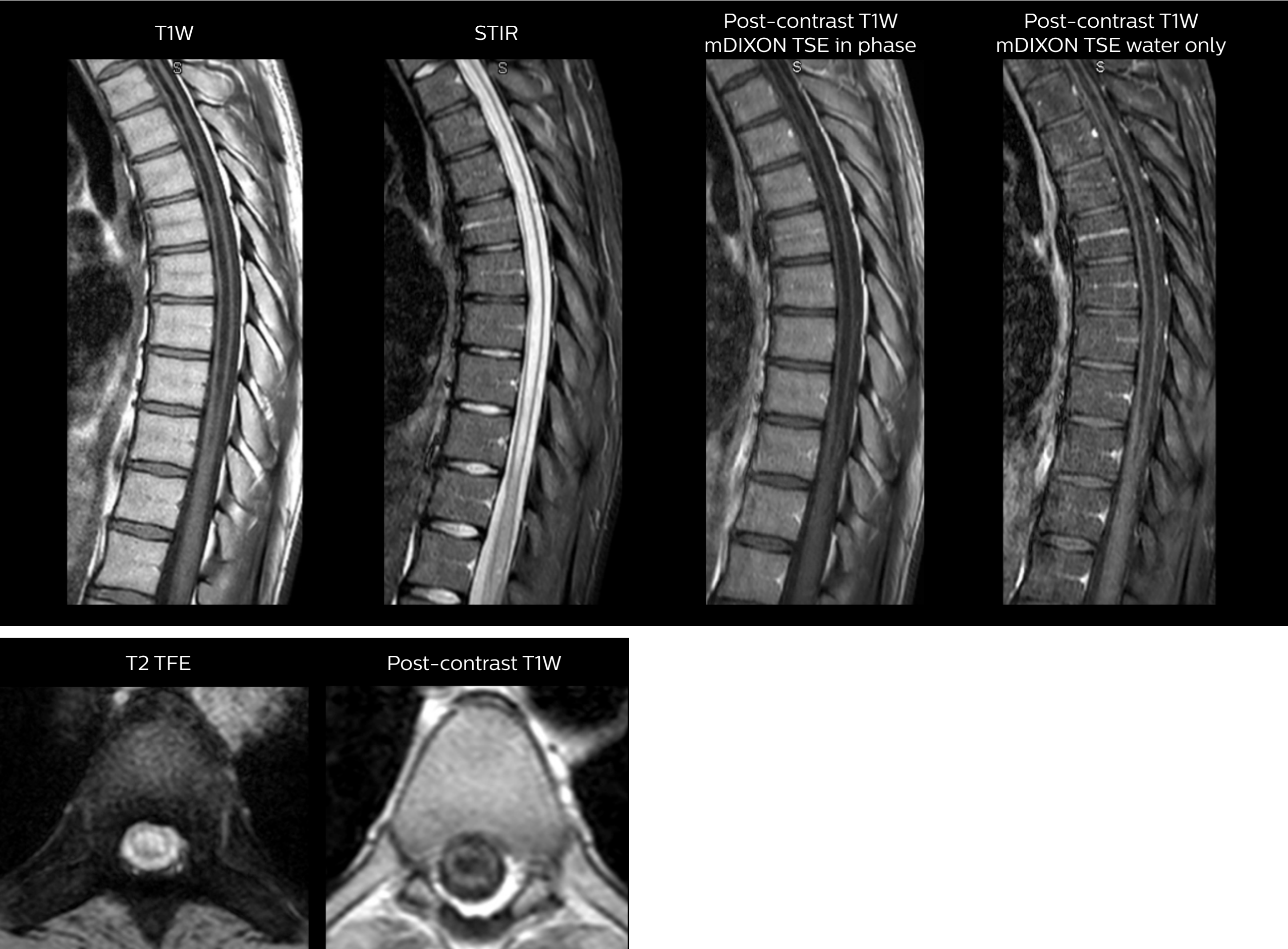
The ED non-contrast brain exam includes sagittal T1W, axial DWI, FLAIR, T2 TFE, total scan time under 9 minutes on Ingenia 1.5T.



Myelopathy imaging: the role of mDIXON

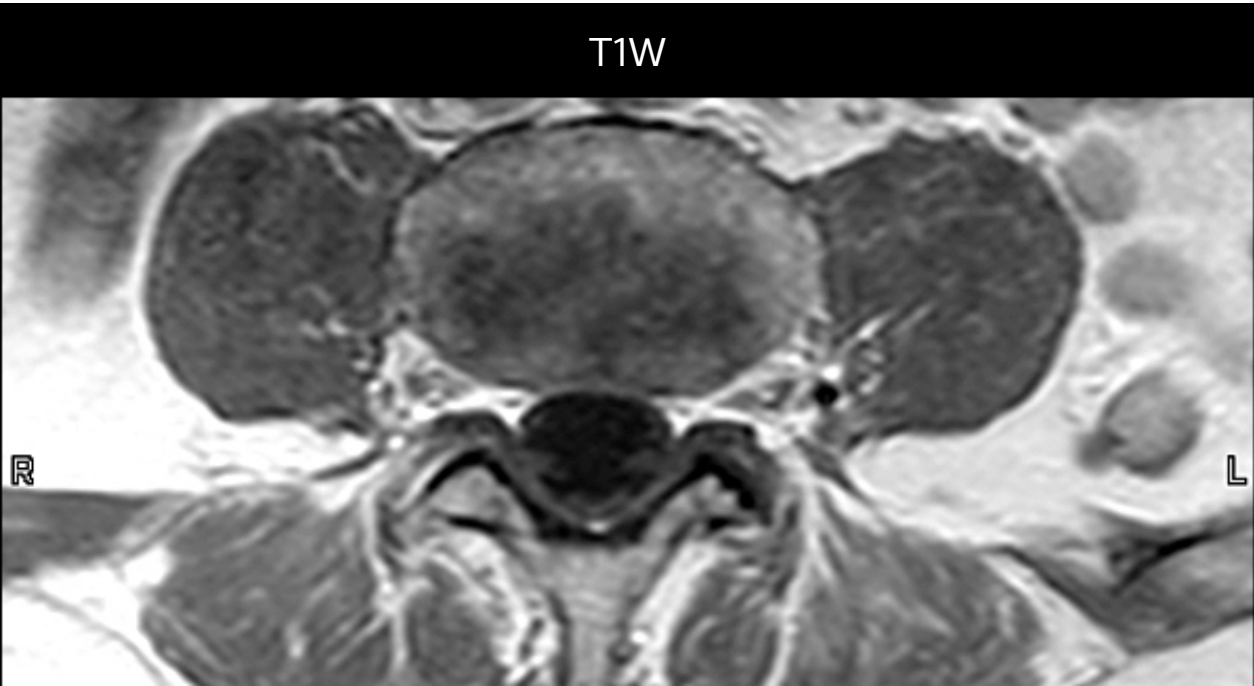
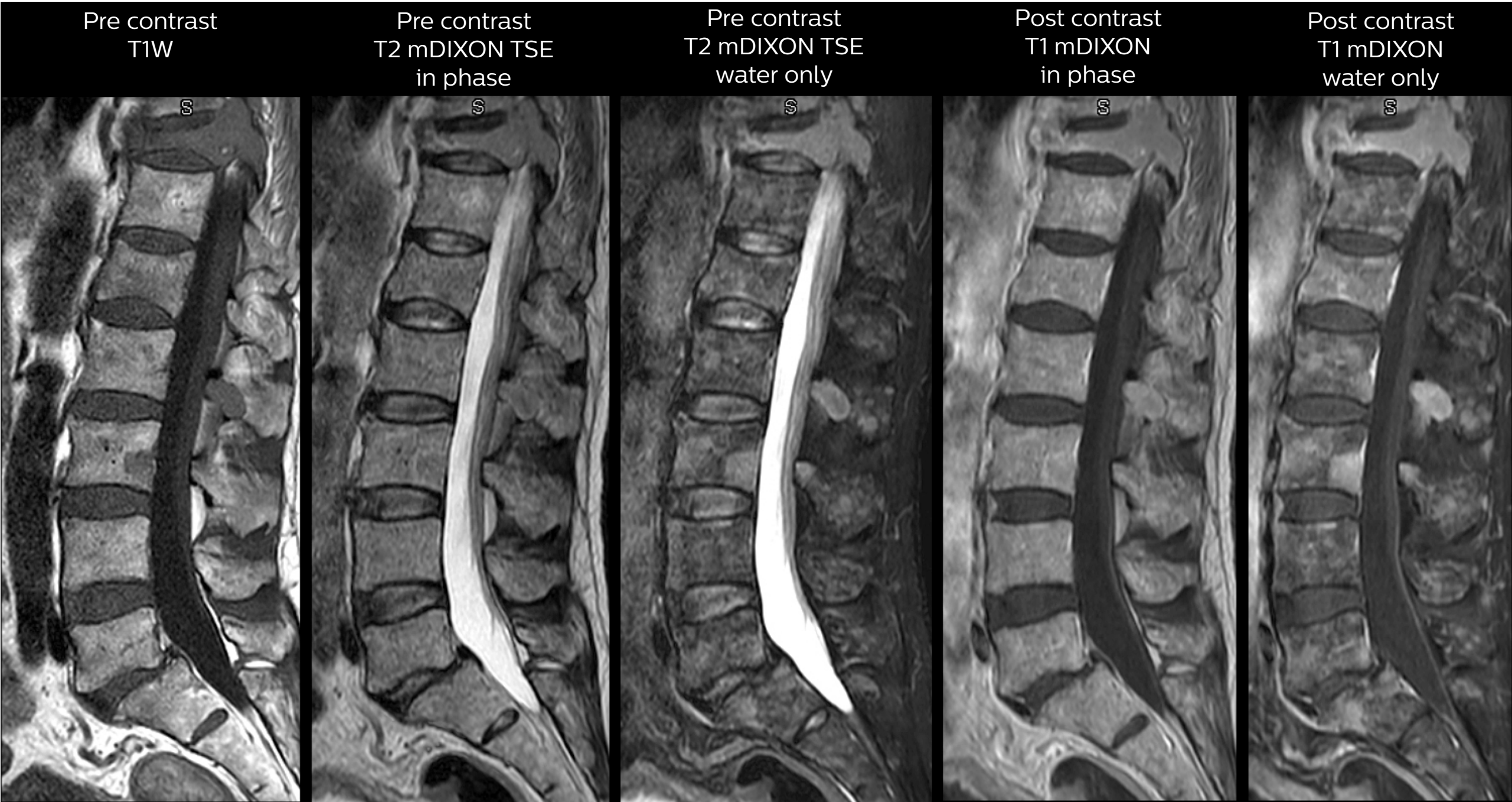
A patient with previously resected metastatic focus from the posterior fossa, presented to the ED with new symptoms of meningismus
Patients with myelopathy are recommended to get a contrast-enhanced study of the cervical or thoracic spine, depending on the level of finding. In case of myelopathy a more traditional STIR exam is used instead of T2W mDIXON because of the slightly improved contrast within the cord. mDIXON is used for post-contrast T1-weighted imaging so that water-only and fat-plus-water post-contrast T1-weighted imaging is available.

Post-contrast axial T1W and axial T2W gradient echo is then performed, targeted to areas where the tech sees a clear finding in the patient in order to keep the scan time short. Performed on Ingenia 1.5T.



MRI helps reveal sources of back pain

This patient with a history of breast cancer presented at the ED with new back pain. The multiple osseous foci are seen on the mDIXON water-only T2-weighted image and the post-contrast mDIXON T1-weighted image. Ingenia 1.5T.



© 2016 Koninklijke Philips N.V. All rights reserved.
Specifications are subject to change without notice.
Trademarks are the property of Koninklijke Philips N.V.
(Royal Philips) or their respective owners.

www.philips.com



How to reach us

Please visit www.philips.com/healthcare
healthcare@philips.com