PHILIPS

Ultrasound

White Paper

Philips Liver Fat Quantification

Fatty liver disease is the most common and earliest stage of chronic liver disease. The incidence of non-alcoholic fatty liver disease (NAFLD) is increased by various risk factors, including insulin resistance and obesity. It is estimated that NAFLD may be present in about 25% of the global population. NAFLD includes simple liver steatosis, as well as more severe forms that include inflammation, a condition called non-alcoholic steatohepatitis (NASH), fibrosis, and cirrhosis. Early assessment of fatty liver is key to potentially reversing this progression of liver disease.[1]

Liver biopsies have been the traditional method for diagnosis of fatty liver disease. However, biopsies present the risks of infection and injury, as well as the variability in results that comes from sampling only small regions in the liver with the biopsy.[2] Magnetic resonance imaging-derived proton density fat fraction (MRI-PDFF) has become adopted as an accurate, reproducible noninvasive imaging biomarker for quantifying liver fat.[3] The challenge with using MRI-PDFF can be the cost and limited access to MRI faced by most of the global population.

Better health outcomes and lower overall cost of care

Ultrasound-based liver fat quantification methods have gained increased attention recently due to the need for a widely accessible noninvasive imaging biomarker to address the prevalence of fatty livers.[4] Clinicians have long recognized that the presence of fat in the liver generates a smooth, hyperechogenic appearance in the liver, especially when compared to the echogenicity of the adjacent kidney. Fat also increases the attenuation of the liver, thereby reducing the ultrasound penetration and the visualization of the deeper structures such as the diaphragm. The Philips Liver Fat Quantification (LFQ) solution allows the user to measure the attenuation of the liver using the attenuation quantification tool and characterize the relative echogenicity of the liver using the hepatorenal index (HRI) tool.

Attenuation quantification

Principles of ultrasound attenuation estimation

The acoustic attenuation coefficient is a tissue-dependent physical property that quantifies how much the acoustic intensity drops in a unit of distance. As ultrasound propagates in soft tissue due to absorption and scattering, the acoustic intensity is reduced. Attenuation can be modeled using the following equation, where **I** is the intensity, **z** is the depth, $\mathbf{z^0}$ is the initial depth, **f** is the frequency, and **α(f)** is the attenuation coefficient (dB/cm):

$$I(f,z) = I(f,z_0)e^{-2*\alpha(f)*(z-z0)} \qquad \text{Equation (1)}$$

For low frequencies, a linear relationship between the attenuation coefficient, **α(f)**, and frequency **f** can be assumed:

$$\alpha(f) = \alpha_0 * f \qquad \text{Equation (2)}$$

α_0 is the acoustic attenuation coefficient slope and has units of dB/cm/MHz. This is the acoustic parameter that is typically reported for different materials and tissue types, and simply referred to as the attenuation of that material or tissue.

In practice, it is not trivial to estimate acoustic attenuation using ultrasound pulse-echo mode. The measured acoustic signal intensity depends not only on the tissue-specific attenuation coefficient but also on several other factors such as the beam diffraction pattern, and the effect of the time gain compensation (TGC) and overall gain. Due to these factors, observed raw signal intensities present more complex profiles than the linear attenuation trend described in Equation (1). In order to estimate the true acoustic attenuation coefficient, these factors must be removed.

LFQ uses the reference phantom-based method to correct for such system dependence. The reference phantom-based method relies on a physical phantom with uniform backscattering strength and known acoustic attenuation coefficient. The system dependent signal change as a function of depth is estimated from the data acquired on this phantom and subsequently removed from the tissue sample under examination.

To obtain a robust measurement of the acoustic coefficient, LFQ estimates it over the bandwidth of the transducer to fully remove any frequency-dependent system bias. With adequate signal-to-noise ratios across the selected bandwidth, averaging over the bandwidth can lower measurement variation.

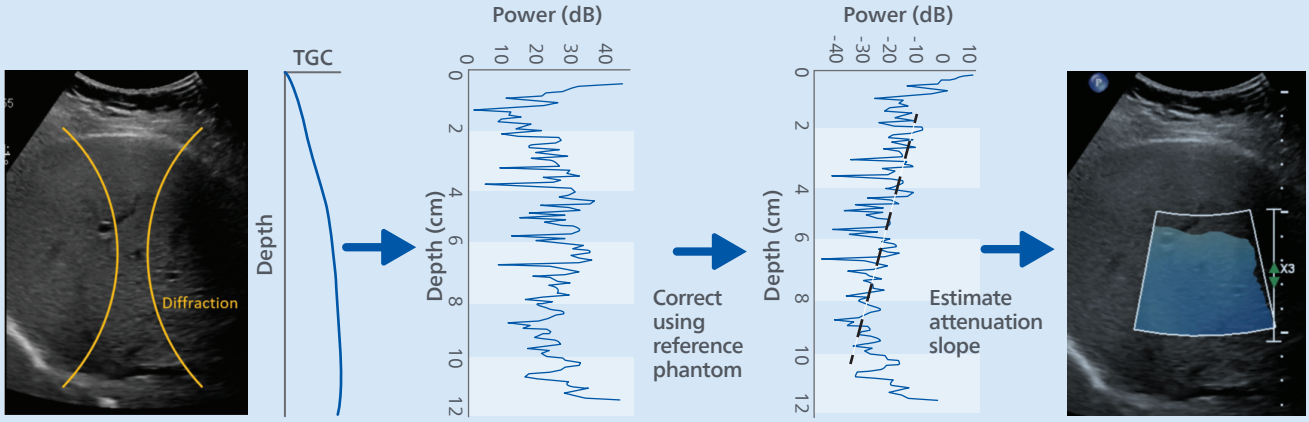

Figure 1 Estimation of attenuation coefficient from one line of acoustic data after correction for system dependence using a reference phantom.

Attenuation confidence map

The reproducibility of attenuation measurements can be increased by following a few clinical guidelines.

- Avoid measuring proximal to the liver capsule which is more prone to reverberation
- Avoid measuring near large blood vessels which affect the backscattered echo brightness
- Use an intercostal window for scanning that minimizes the acoustic shadowing from ribs or blockage of the transducer aperture

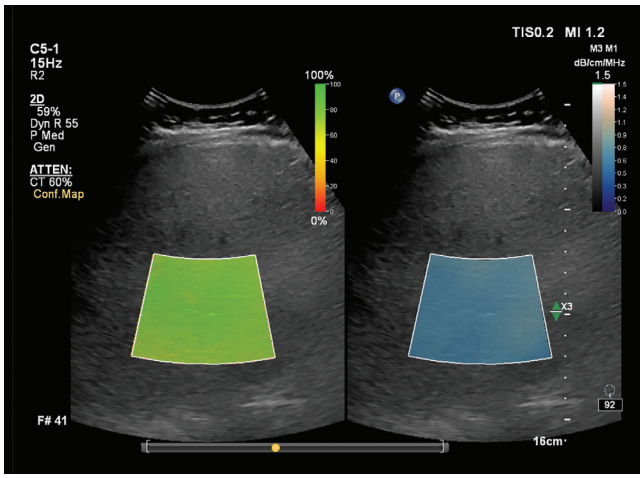

Figure 2 This liver is uniform and artifact-free in this acquisition and the confidence map reflects this by showing uniformly high confidence over the entire attenuation imaging region.

A confidence map is available in the attenuation tool to facilitate the placement of the attenuation region-of-interest sample based on these best practice guidelines. The confidence is computed at every pixel within the Atten colorbox and will return a low score if placed near anatomic boundaries if the signal-to-noise ratio of the underlying data is poor or if the attenuation estimate is not consistent over the frequency range covered by the transducer frequency bandwidth. The confidence score varies from 0% (very poor) to 100% (excellent) and can be visualized by enabling the "Confidence Map" option from the touchscreen. **Figure 2** shows a typical attenuation image acquired with best practice with high confidence. **Figures 3** and **4** show areas of poor confidence due to large blood vessels and reverberation from the liver capsule, respectively.

In addition, the confidence feature provides a user-controlled confidence threshold (CT) which masks area of confidence (e.g., confidence < CT) within the attenuation box. Samples that are hidden by the confidence threshold will not be counted when placing a measurement circle. The default CT cut-off was chosen to accommodate a variety of body habitus.

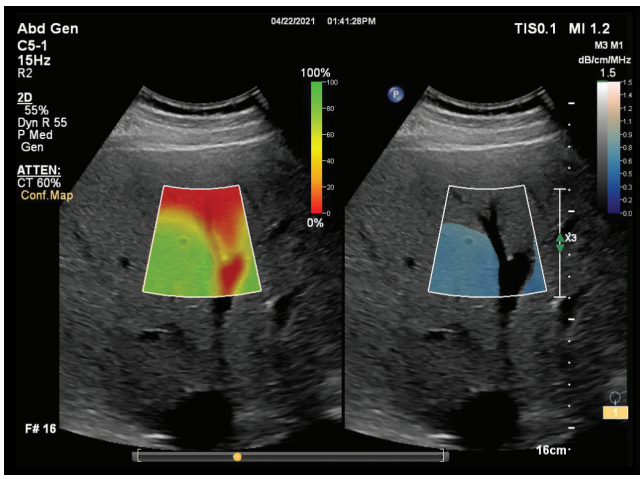

Figure 3 The confidence map detects the presence of several vessels in the attenuation imaging region and flags these as regions of low confidence (red). There is also so reverberation from the abdominal wall, resulting in reduced confidence levels at the shallower depths.

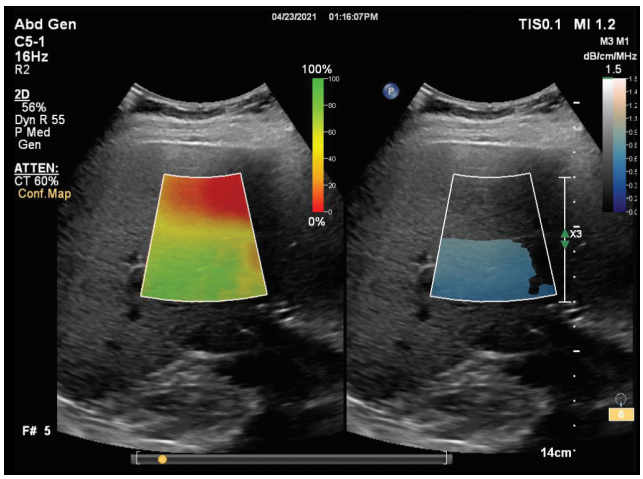

Figure 4 The confidence map detects the presence of an acoustic shadow on the right side of the attenuation image region and identifies this as a region of low confidence (red) . Strong reverberation from the abdominal wall also reduces the confidence level in the shallow portion of the attenuation region.

Attenuation quantification user interface

Figure 5 Attenuation quantification touchscreen.

The Liver Quant button on the touchscreen **(Figure 5)** allows the user access to the full suite of quantitative ultrasound tools for liver assessment. Once Liver Quant is selected, hitting Atten will enable Attenuation Quantification. The default layout for Attenuation Quantification is a side-by-side display where the attenuation estimates are shown on the right side, inside the attenuation imaging region **(Figure 6)**. To get a quantitative measurement, select Measure and place the circular region-of-interest (ROI) over the attenuation image. The attenuation measurement is typically displayed as either the average or median of the values within the ROI. Estimates from locations that are below the confidence threshold are not displayed in the attenuation image, and do not contribute to the measured attenuation value. The confidence map can also be displayed or hidden using a button on the touchscreen. It is important to note that the confidence map is always active in the background and will eliminate low confidence attenuation estimates even if it is not displayed.

Attenuation measurements can also be done retrospectively in Review, using captured loops while in Atten. This conveniently allows the user to repeat a measurement later, if needed, even after the patient is no longer present.

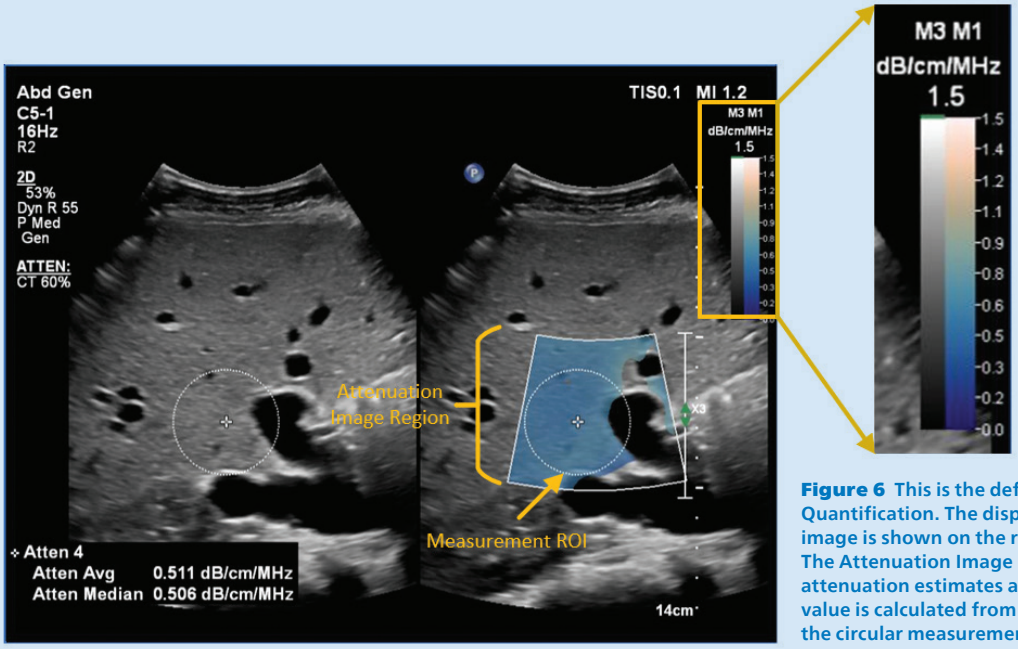

Figure 6 This is the default screen for Attenuation Quantification. The display range for the attenuation image is shown on the right, from 0 to 1.5 dB/cm/MHz. The Attenuation Image Region is where the color-coded attenuation estimates are shown. The displayed attenuation value is calculated from all the displayed samples within the circular measurement ROI.

Scanning and measurement tips for attenuation quantification

The patient should be positioned either supine or slight lateral decubitus (30°) position with the right arm in extension **(Figure 7)**. The transducer should be positioned in the right intercostal space and aligned with the ribs to minimize any shadowing. Image liver segment 7 or 8 with the scan plane ideally showing uniform liver parenchyma and avoiding major vessels. Pausing breathing may help with getting a good image, although that is not strictly necessary. The start depth of the attenuation imaging region should be about twice the abdominal wall thickness to avoid the reverberation from within the abdominal wall. Place the measurement ROI so as to maximize the fill within the ROI **(Figure 8)**.

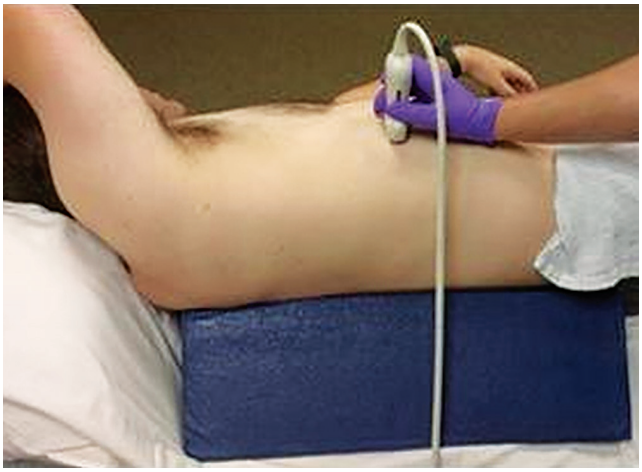

Figure 7 Patient positioning for measuring liver attenuation.

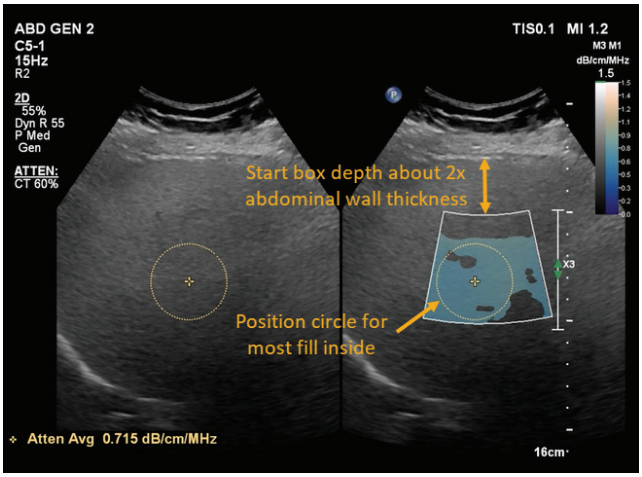

Figure 8 Suggested positioning of attenuation imaging region and measurement ROI.

Principles of measuring the hepatorenal index (HRI)

HRI has been used clinically for fatty liver detection for many years.[5,6] In brief, the ultrasound echo amplitude is calculated by selecting regions of interest (ROIs) within the liver parenchyma and the kidney cortex at the same depth, and by evaluating the ratio between the average echo amplitude in the liver ROI over that of the kidney ROI. Excessive fat infiltration in the liver increases acoustic backscattering, thereby leading to higher echo amplitude values from the liver in the ultrasound 2D image. At a normal state, liver parenchyma and renal cortex have similar echogenicity. With more at deposits, the liver will appear more hyperechoic (i.e., brighter) than the kidney cortex.

Conventionally, HRI can be calculated using grayscale 2D images acquired as DICOM images. However, due to multiple system dependencies (gain, dynamic range, gray map), calculating HRI from DICOM images introduces a lot of variability and makes the result highly dependent on the specific acquisition setting used. The Philips HRI quantification tool works on-cart and within the signal processing chain of the ultrasound system. Operator-dependent system settings such as compression, gain and gray maps are known and can be compensated for prior to calculating the HRI value. The net result is an HRI measurement that is consistent despite different user imaging preferences.

HRI user interface

HRI can be accessed through the Liver Quant button on the touchscreen, followed by the HRI button, as shown (**Figure 9**). The HRI label on the main display indicates that you are in the HRI mode and that HRI measurements can be made.

Figure 9 HRI touchscreen.

To acquire the HRI measurement, select Measure on the control panel. You will be prompted to place the first ROI inside the kidney. Once the ROI is set, the second ROI will be automatically launched, and you will be prompted to place the second ROI in the liver. The HRI result will automatically be calculated.

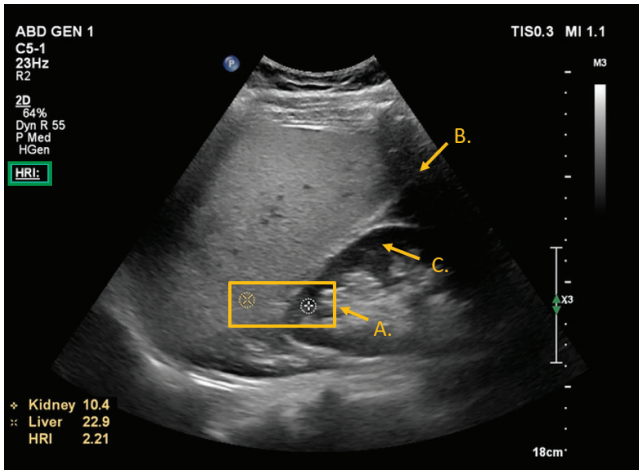

Figure 10 HRI image showing the placement of first ROI in the kidney and the second ROI in the liver. The HRI indicator (highlighted by the green box) shows that HRI is active. **Arrow A** shows both ROIs at a similar depth. **Arrow B** shows a region of acoustic shadowing from ribs. **Arrow C** shows the shadowing created by the kidney capsule when the acoustic beam is close to perpendicular to the capsule.

Some tips for getting a good HRI result (**Figure 10**).

- Place both ROIs for the liver and kidney at the same depth. This ensures that the influence of TGC and focusing are similar for both ROIs (arrow A).
- Avoid placing the ROI in regions marked by acoustic rib shadows as this will affect the echogenicity of the ROI (arrow B).
- Avoid placing the ROI immediately under the kidney capsule (arrow C).

Summary of clinical study data

One hundred and fourteen liver patients suspected of having or diagnosed with NAFLD/NASH were enrolled in a prospective clinical study at three clinical sites from August 2018 to July 2019. The results from one site was previously published in d'Hondt.[7] The patient numbers from each site as well as the MR equipment used is summarized in **Table 1**.

Each subject underwent an ultrasound exam (Philips EPIQ system with C5-1 transducer) and a standard MRI-PDFF exam. All imaging procedures (ultrasound exam and MRI-PDFF exam) were completed within a time window of no more than eight weeks for all the patients.

Clinical institute	Patient number	Gender (M/F)	Age (y)	MRI system
Stanford Radiology	35	15/20	52 ±15	GE Discovery 3T
Stanford Lucile Packard Children's Hospital	48	26/22	13 ± 3	GE Optima 1.5T and Discovery 3T
Boston Medical Center	31	10/21	40 ±12	Philips Ingenia 3T

Table 1 Patient demographics and MRI used for MRI-PDFF measurements.

The MRI-PDFF value is referenced as the ground truth for liver fat percentage. Hepatic steatosis stage is defined as normal (S0), mild (S1), moderate (S2) and severe (S3), using 5%, 10% and 20% MRI-PDFF cutoffs.[8] Among the 114 patients, 63 subjects (55%) have steatosis stage S0, 18 subjects (16%) have S1, 15 subjects (13%) have S2 and 18 subjects (16%) are classified with the severe steatosis stage S3. The overall distribution is illustrated (**Figure 11**).

Ultrasound raw data was acquired in real time and analyzed off-line to derive the acoustic attenuation coefficient. The Pearson correlation coefficient (R) was used to assess the correlation between attenuation and the measured liver fat percentage obtained from MRI-PDFF. The acoustic attenuation coefficient showed strong correlation with MRI-PDFF, with R=0.79 (95% CI 0.71-0.85, p<0.0001, n=114).

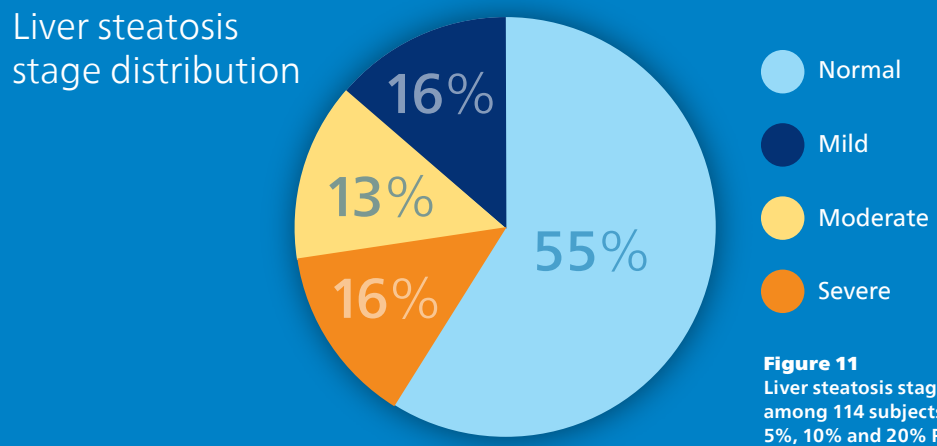

Figure 11
Liver steatosis stage distribution among 114 subjects assessed by 5%, 10% and 20% PDFF cutoffs.

Figure 110 presents the scatter plot with a linear trend line between attenuation coefficient and MRI-PDFF measurements.

To examine attenuation coefficient as a function of the liver steatosis stage, a box and whisker plot was used to visualize the distribution in each steatosis stage, as shown in **Figure 13**. The attenuation coefficient increased with the stage of hepatic steatosis assessed by MRI-PDFF.

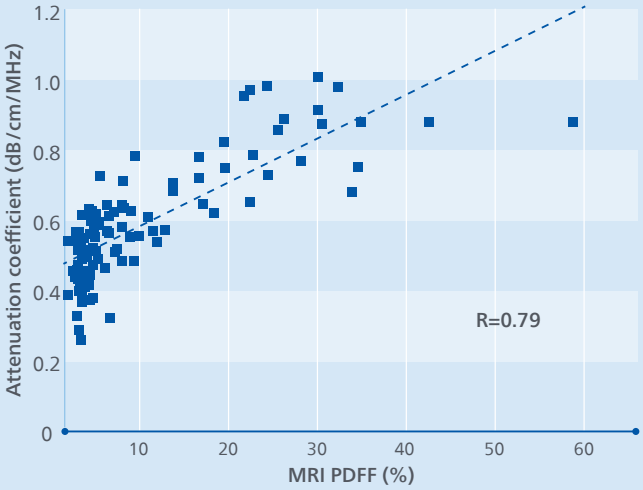

Figure 12 Correlation between MRI-PDFF and attenuation coefficient over 114 subjects.

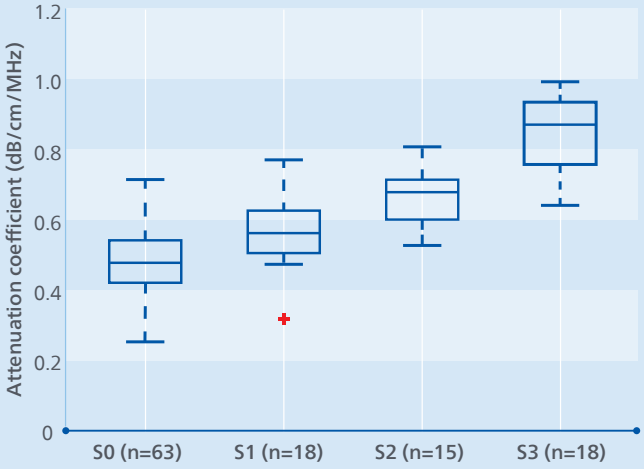

Figure 13 Measured attenuation coefficient for each liver steatosis stage graded by MRI-PDFF.

Conclusion

The Philips Liver Fat Quantification package consists of attenuation quantification and HRI. These tools provide simple, intuitive tools to assist physicians in managing patients with chronic liver disease. The confidence map provided with attenuation quantification guides the user towards placing the measurement ROI in high confidence regions that avoid common ultrasound imaging artifacts, thereby allowing high quality, reproducible measurements of liver attenuation.

References

1. Younossi ZM. Non-alcoholic fatty liver disease - A global public health perspective. J Hepatol. 2019;70(3):531-544.
2. Nalbantoglu IL, Brunt EM. Role of liver biopsy in nonalcoholic fatty liver disease. World journal of gastroenterology : WJG. 2014;20(27):9026-37.
3. Middleton MS, Van Natta ML, Heba ER, et al. Diagnostic accuracy of magnetic resonance imaging hepatic proton density fat fraction in pediatric nonalcoholic fatty liver disease. Hepatology. 2018;67(3):858-872.
4. Ferraioli G, Berzigotti A, Barr RG, et al. Quantification of Liver Fat Content with Ultrasound: A WFUMB Position Paper. Ultrasound Med Biol. 2021;47(10):2803-2820.
5. Webb M, Yeshua H, Zelber-Sagi S, et al. Diagnostic value of a computerized hepatorenal index for sonographic quantification of liver steatosis. AJR Am J Roentgenol. 2009;192(4):909-914.
6. Marshall RH, Eissa M, Bluth EI, Gulotta PM, Davis NK. Hepatorenal index as an accurate, simple, and effective tool in screening for steatosis. AJR Am J Roentgenol. 2012;199(5):997-1002.
7. D'Hondt A, Rubesova E, Xie H, Shamdasani V, Barth RA. Liver Fat Quantification by Ultrasound in Children: A Prospective Study [published online ahead of print, 2021 Aug 25]. AJR Am J Roentgenol. 2021;1-11.
8. Caussy C, Alquiraish MH, Nguyen P, et al. Optimal threshold of controlled attenuation parameter with MRI-PDFF as the gold standard for the detection of hepatic steatosis. Hepatology. 2018;67(4):1348-1359.

© 2021 Koninklijke Philips N.V. All rights are reserved. Philips reserves the right to make changes in specifications and/or to discontinue any product at any time without notice or obligation and will not be liable for any consequences resulting from the use of this publication. Trademarks are the property of Koninklijke Philips N.V. or their respective owners.

www.philips.com

Printed in the Netherlands.
4522 991 72241 * NOV 2021