


**PHILIPS**

*Tack*

Endovascular system (6F)

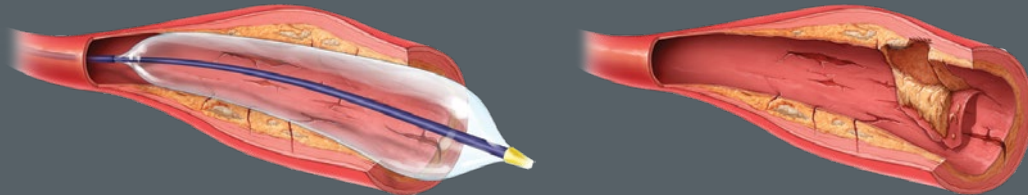
# Optimize above-the-knee PTA with precision dissection repair



# Dissections are inevitable

Balloon angioplasty is a proven and effective method to treat peripheral artery disease (PAD) in the superficial femoral (SFA) and popliteal arteries, but the mechanism of angioplasty inevitably creates arterial dissections. Left untreated, these dissections may obstruct blood flow both immediately and in the long term. They demonstrate high restenosis and reintervention rates so it is important to repair them when they occur in order to maintain vessel integrity and improve patency.<sup>1</sup>

Balloon angioplasty uses multi-directional force to increase the arterial lumen, injuring the vessel wall.



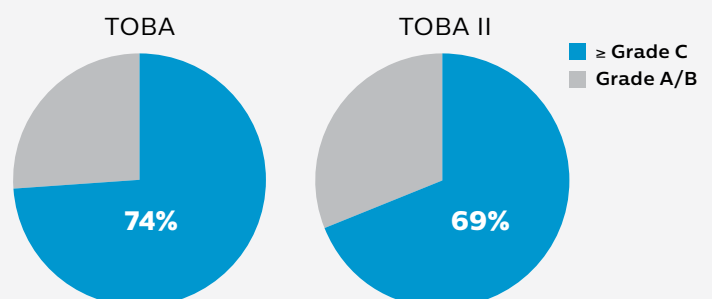
*Clinical evidence proves that dissections matter.<sup>2,6</sup>*

## Dissections are prevalent, underdiagnosed and underestimated

Studies show that post-percutaneous transluminal angioplasty (PTA) dissections are prevalent, underdiagnosed and underestimated, leading to increased risk for PAD patients, even after undergoing treatment for their disease.<sup>2,6</sup>

**Prevalent** – Dissections are visible on angiography in up to 84% of above-the-knee (ATK) angioplasties.<sup>2</sup> In the Tack Optimized Balloon Angioplasty (TOBA and TOBA II) trials, the angiographic core lab adjudicated 69-74% of dissections as  $\geq$  Grade C (**Figure 1**).<sup>3-4</sup>

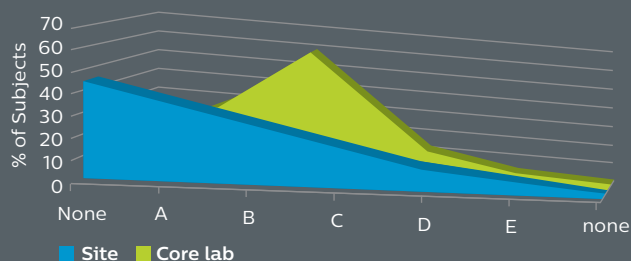
**Figure 1: Rates of severe dissection post-PTA**  
(core lab adjudicated)



**Underdiagnosed** – Dissections can be misinterpreted or missed if viewed from only one angle, and/or without magnification. Studies using intravascular ultrasound (IVUS) have shown dissections are more numerous and more severe than what is seen angiographically.<sup>5</sup>

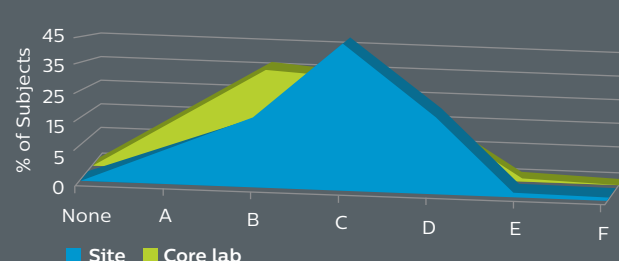
**Underestimated** – In the TOBA trial, investigators graded dissections as  $\geq$  Grade C in 25.8% of cases, compared with the core lab at 74.0% (**Figure 2**).<sup>3</sup> Correlation improved in TOBA II with dissection training (**Figure 3**).<sup>4</sup>

**Figure 2:** TOBA: Baseline dissection grade



Major disparity between site-reported and core lab dissection grade

**Figure 3:** TOBA II: Baseline dissection grade



Strong correlation between site-reported and core lab dissection grade after training

## Dissections matter

While there is consensus that severe dissections result in poorer outcomes, recent studies demonstrate that any untreated dissection can negatively impact vessel patency, target lesion revascularization (TLR) rates, and patient outcomes.<sup>2,6</sup>

**Dissections are an inherent result of angioplasty and they matter, regardless of severity.**

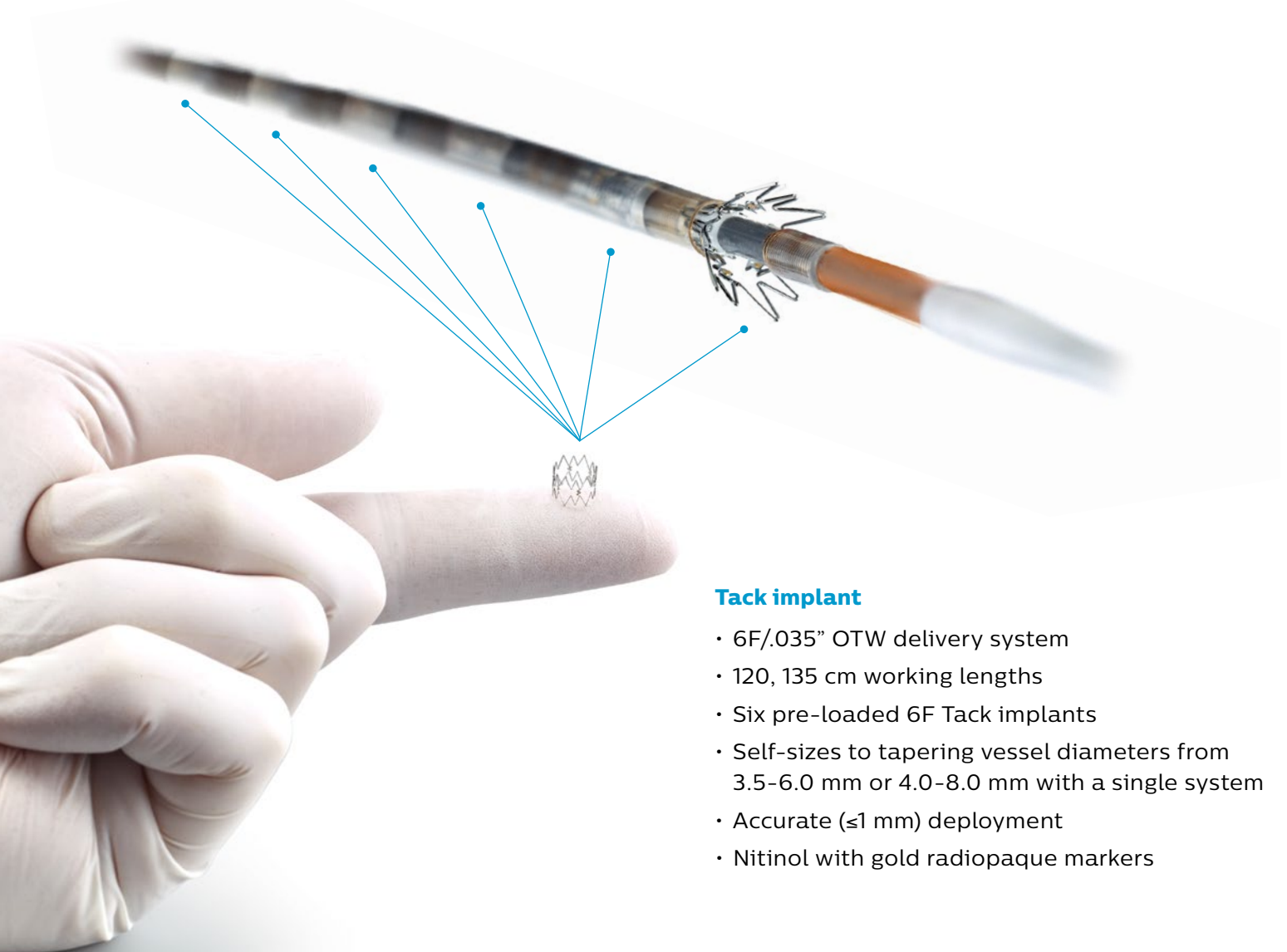
*In the THUNDER study, Grade A-B dissections experienced similar rates of 6-month TLR as did Grades C-E (33% and 44%, respectively). At 24 months, TLR rates increased to 43% for Grades A-B and 78% for Grades C-E.<sup>6</sup>*

# Tack endovascular system

The Tack endovascular system is an adjunct therapy to balloon angioplasty, purpose-built for precision dissection repair to promote healing, improve outcomes and preserve limbs.

A purpose-built solution to successfully repair dissections caused by balloon angioplasty in ATK therapeutic interventions, the Tack endovascular system (6F) provides precision treatment using minimal metal. This first-of-its-kind implant, designed to repair dissections with high rates of patency and freedom from CD-TLR, ultimately preserves future treatment options.

The Tack endovascular system is an adjunct therapy to plain balloon angioplasty (POBA) and drug-coated balloon (DCB) procedures and is specifically designed to support long-term patency and improve outcomes. Pre-loaded with six self-expanding nitinol implants that can be precisely deployed to treat multiple dissections with a single catheter, a Tack implant leaves behind >70% less metal than stents.<sup>3</sup>



## Tack implant

- 6F/.035" OTW delivery system
- 120, 135 cm working lengths
- Six pre-loaded 6F Tack implants
- Self-sizes to tapering vessel diameters from 3.5-6.0 mm or 4.0-8.0 mm with a single system
- Accurate ( $\leq 1$  mm) deployment
- Nitinol with gold radiopaque markers

## Purpose-built

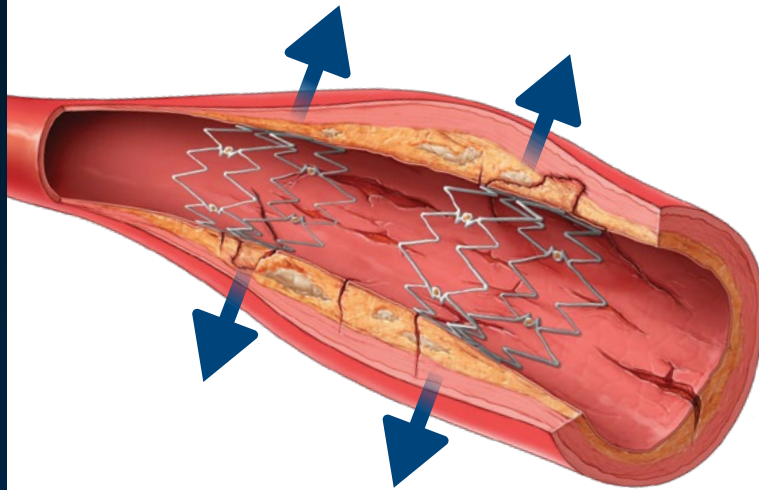
The Tack endovascular system is purpose-built to repair peripheral arterial dissections following balloon angioplasty in ATK therapeutic interventions.

## Precision repair

Focal treatment with minimal metal treats only the area where dissections are present and avoids covering portions of healthy tissue.

## Preserves options

A Tack implant leaves behind >70% less metal than traditional stents,<sup>3</sup> preserving vessel integrity, future treatment options and – ultimately – limbs.



## No more device sizing

Only the Tack endovascular system features **adaptive sizing** – which allows each Tack implant to adapt to tapering anatomy while maintaining a relatively constant radial force. This means that a single size Tack implant can be used across a wide range of vessel diameters.

Delivery system



# Clinical data

## TOBA II

This multi-center, pivotal trial studied the Tack endovascular system (6F, 3.5-6.0 mm) in patients with post-PTA dissection following POBA or Lutonix DCB in the SFA and proximal popliteal arteries.\* The trial enrolled 213 patients with at least one post-PTA dissection, with 69.4% adjudicated as severe.<sup>4</sup>

### Key results<sup>4</sup>

**92.1%**

Dissection resolution

**86.5%**

12-month K-M freedom from CD-TLR

**79.3%**

12-month K-M primary patency

**100%**

Freedom from fracture

**99.9%**

12-month freedom from implant migration<sup>†</sup>

**0.5%**

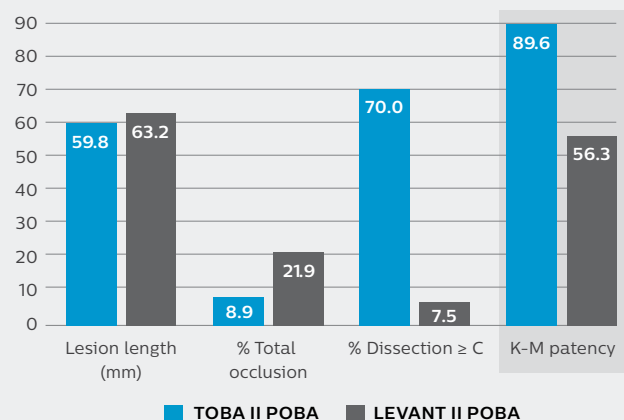
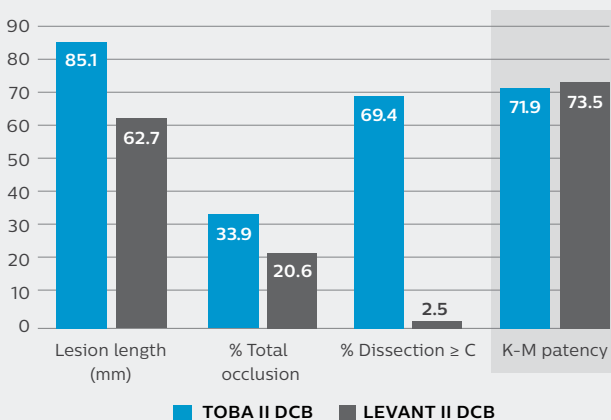
Bail out stent rate

<sup>†</sup>2.6 mm per core lab at 12-month x-ray

## Patency observations in TOBA II<sup>†</sup>

DCB patients had longer lesions and more total occlusions. Compared with the LEVANT II trial,<sup>7</sup> the Tack endovascular system demonstrated a DCB-like patency rate in a more complicated (100% dissected vessels) patient population.

POBA patients had fewer total occlusions, yet more severe dissections. The Tack endovascular system had a notably higher patency rate than the POBA arm in LEVANT II.



\*Balloon choice was at the discretion of the physician.

<sup>†</sup>Observational data only; patient populations and study methodology differed; not powered for statistical significance.

The Tack endovascular system has been rigorously studied in the TOBA trials. These trials are unique in that they are the only clinical trials to investigate 100% dissected vessels.

## TOBA III

This European multi-center post-CE Mark study continues the evaluation of dissection repair with the Tack endovascular system (6F, 3.5–6.0 mm) following DCB with the IN.PACT Admiral in the SFA and proximal popliteal arteries (N=201). The study enrolled 169 patients with standard lesions  $\leq 150$  mm, and 32 patients with long lesions  $>150$  mm and  $\leq 250$  mm.<sup>8</sup>

### Standard lesion key results<sup>8</sup>

97.7%

Dissection resolution

97.5%

12-month K-M freedom from CD-TLR

95.0%

12-month K-M primary patency

0.6%

Bail out stent rate

### Long lesion key results

98.8%

Dissection resolution

96.8%

12-month K-M freedom from CD-TLR


89.3%

12-month K-M primary patency

0.0%

Bail out stent rate

*TOBA II and TOBA III successfully met primary safety and efficacy endpoints demonstrating that post-PTA dissection repair with the Tack endovascular system improves patency and freedom from CD-TLR for both POBA and DCB angioplasty.*



## Dissections matter

While post-PTA dissections are consistently underdiagnosed and underestimated, they are inevitable and should be repaired to reduce the risk of revascularization and optimize patient outcomes. **The Tack endovascular system is a first-of-its-kind minimal metal implant that effectively repairs dissections and improves post-angioplasty outcomes regardless of balloon choice.**<sup>4,8</sup>



#### References

1. Armstrong EJ, Brodmann M, Deaton DH, Gray WA, Jaff MR, Lichtenberg M, Rundback JH, Schneider PA. Dissections After Infrainguinal Percutaneous Transluminal Angioplasty: A Systematic Review and Current State of Clinical Evidence. *J Endovasc Ther* 2019 Aug;26(4):479-489.
2. Fujihara M, Takahara M, Sasaki S et al. Angiographic dissection patterns and patency outcomes after balloon angioplasty for superficial femoral artery disease. *J Endovasc Ther* 2017;1-9.
3. Bosiers M, Scheinert D, Hendriks JMH et al. Results from the Tack Optimized Balloon Angioplasty (TOBA) study demonstrate the benefits of minimal metal implants for dissection repair after angioplasty. *J Vasc Surg* 2016;64:109-16.
4. Gray WA, Cardenas JA, Brodmann M., et al. Treating post-angioplasty dissection in the femoropopliteal arteries using the Tack Endovascular System: 12-month results from the TOBA II study. *J Am Coll Cardiol Intv* 2019;12:2375-84.
5. Shamma NW, Torey JT, Shamma WJ et al. Intravascular ultrasound assessment and correlation with angiographic findings demonstrating femoropopliteal arterial dissections post atherectomy: results from the iDissection study. *J Invasiv Cardiol* 2018;30(7):240-244.
6. Tepe G, Zeller T, Schnorr B et al. High-grade, non-flow-limiting dissections do not negatively impact long-term outcome after paclitaxel-coated balloon angioplasty: an additional analysis from the THUNDER study. *J Endovasc Ther* 2013;20:792-800.
7. Rosenfield K, Jaff MR, White CJ et al. Trial of a paclitaxel-coated balloon for femoropopliteal artery disease. *N Engl J Med* 2015;2:145-53.
8. Brodmann M, Wissgott C, Brechtel K, et al. Optimized drug-coated balloon angioplasty of the superficial femoral and proximal popliteal arteries using the Tack Endovascular System: TOBA III 12-month results. *J Vasc Surg*. 2020;S0741-5214(20)30330-X.

#### Intended use:

The Tack endovascular system (6F, 3.5-6.0 mm and 4.0-8.0 mm) is intended for use in the superficial femoral and proximal popliteal arteries ranging in diameter from 3.5 mm to 6.0 mm and 4.0 mm to 8.0 mm for the repair of post percutaneous transluminal balloon angioplasty (PTA) dissection(s).

#### Contraindications for use:

The Tack endovascular system is contraindicated for the following:

1. Patients with residual stenosis in the treated segment equal to or greater than 30% after PTA.
2. Tortuous vascular anatomy significant enough to prevent safe introduction and passage of the device.
3. Patients with a known hypersensitivity to nickel-titanium alloy (Nitinol).
4. Patients unable to receive standard medication used for interventional procedures such as anticoagulants, contrast agents and antiplatelet therapy.

Prior to using the Tack endovascular system, please review the instructions for use for a complete listing of indications, contraindications, warnings, precautions, potential adverse events and directions for use.

Tack endovascular system and Tack are registered trademarks of Intact Vascular, Inc. Adaptive sizing is a trademark of Intact Vascular, Inc.

Caution: Federal law restricts this device to sale by or on the order of a physician.