

Transcatheter aortic valve implantation in a hybrid operating room using HeartNavigator

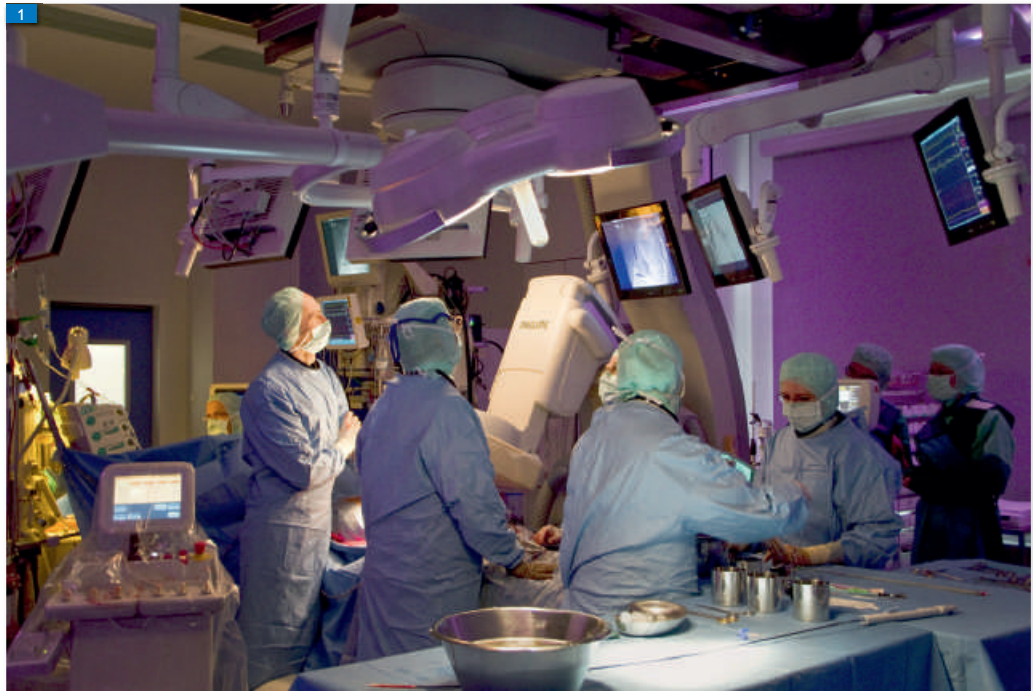The article here is reprinted by permission of MEDICAMUNDI, a publication of Philips Healthcare Nederland B.V., Volume 54, Issue 3

Transcatheter aortic valve implantation in a hybrid operating room using HeartNavigator

H. Schröfel Klinik für Herzchirurgie, Karlsruhe, Germany.

N.H. Bakker Philips Healthcare, Best, the Netherlands.
R. van den Boomen

▶ Figure 1. The hybrid operating room.



▶ **The transcatheter procedure offers important advantages over open heart surgery.**

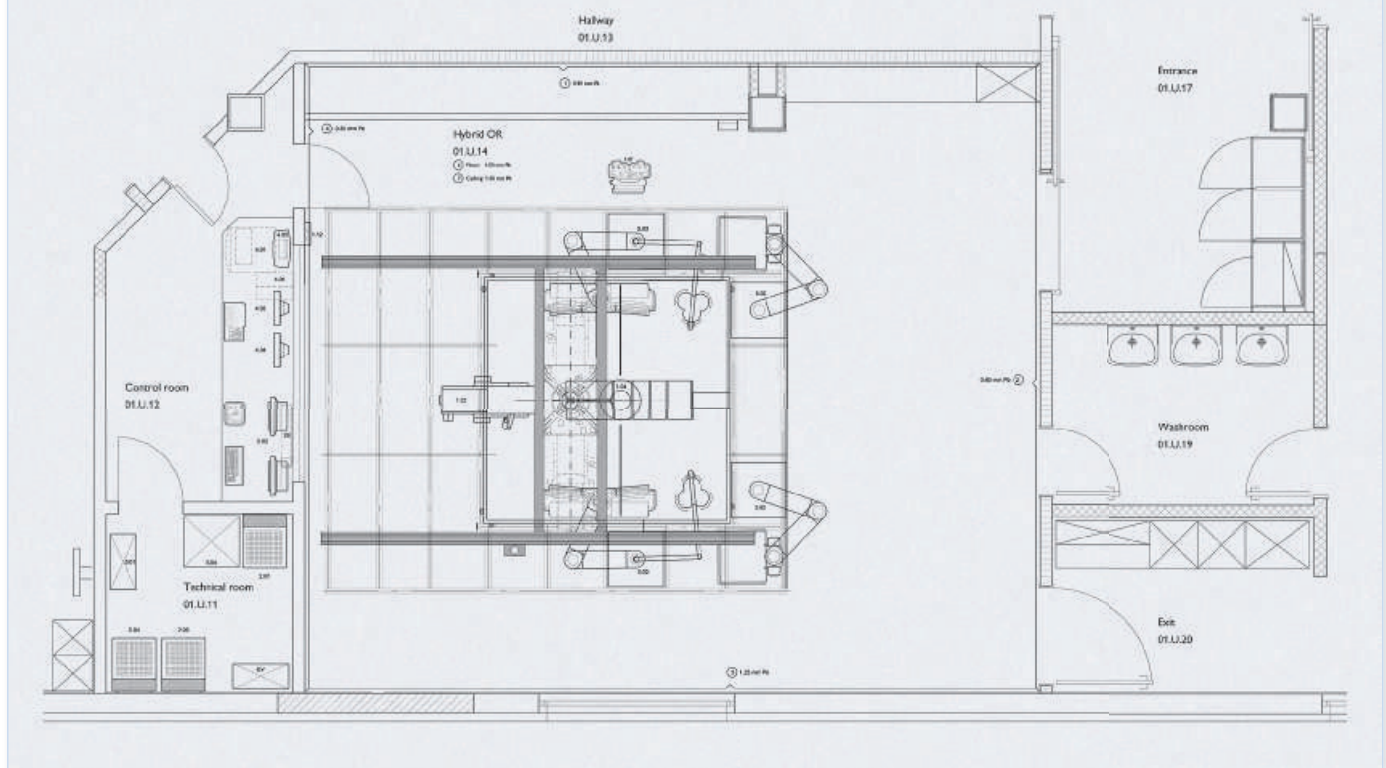
Opened in 1995, the Klinik für Herzchirurgie Karlsruhe (Karlsruhe Heart Surgery Clinic) is a specialist hospital for the treatment of heart disease in adults, carrying out some 2,500 procedures per year. With the introduction of minimally invasive techniques, including aortic and mitral valve replacement, the hospital is regarded as being a center of excellence for the treatment of heart patients. The hospital serves the City of Karlsruhe and the surrounding area, comprising some 400,000 inhabitants, but candidates for transcatheter aortic heart valve implantation (TAVI) are referred from outside the area.

In 2007/2008 our TAVI team visited the leading heart center in Leipzig, Germany (Herzzentrum Leipzig GmbH – Universitätsklinik) to observe the procedures for transcatheter valve implantation. The TAVI team consists of Dr. Schröfel and Dr. Posival (Klinik für Herzchirurgie, Karlsruhe), Dr. Schymik and Prof. Schmitt (Kardiologie Städtisches Klinikum, Karlsruhe), and Dr. Würth and Prof. Gonska (Kardiologie St. Vincentius Kliniken Karlsruhe). It was obvious that the transcatheter procedure offers

important advantages over open heart surgery, particularly in older and critically ill patients.

Following a short training course in Leipzig, our team began their own TAVI program in 2008, using a mobile C-arm X-ray system in a conventional operating room. Experts from Leipzig, Prof Sack and Prof Walther, provided assistance and support during the initial phase. During the first nine months, 125 patients were treated, approximately evenly divided between the transfemoral and transapical approach. The results were very encouraging, and the procedure was easy to integrate in the clinical routine.

However, performing TAVI procedures in a conventional operating room is essentially a compromise. The mobile X-ray system cannot provide the high-quality imaging needed to visualize thin guide wires, quantify small vessel diameters, and ensure accurate placement of intravascular devices. Moreover, the limited heat capacity becomes a significant problem in lengthy procedures. Transcatheter implantation of an aortic valve, in particular, demands high-quality imaging and precise navigation,



to ensure accurate positioning. An alternative could be to perform the procedures in a cath lab, but this would not meet all of the requirements for surgery, particularly with respect to sterility.

For this reason, the clinic opted for a “hybrid” operating room.

The hybrid operating room

A hybrid operating room (hybrid OR) is a specialized operating room with a fixed high-end imaging system, enabling interventional techniques and open surgery to be performed in the same location. The hybrid OR needs to be larger than a standard operating room, to allow for the imaging equipment and also to accommodate the multidisciplinary team, including the anesthesiologist, cardiac surgeon, interventional cardiologist, nurses, technicians, etc. [1].

Planning and construction of the hybrid OR demands specialized architectural expertise. The room must meet all the requirements of an operating room, including maintenance of asepsis and laminar airflow, but must also meet the requirements of a radiology room, including lead shielding (2-3 mm) and reinforcement of the ceiling or floor to take the weight of the X-ray system (approx. 650 – 1800 kg).

In our case we were fortunate enough to be able to create an entirely new room for the hybrid OR. This room has an area of 70 m². Together with the

technical room, washroom and control room the whole suite has an area of 110 m² (Figures 1, 2). The hybrid OR was planned and developed in close collaboration with Philips Healthcare, and was brought into use in February 2009. To date, some 500 patients have been treated in the room.

A significant advantage of the hybrid OR is that all technologies for treating patients either surgically or interventionally are available in the same room. If any complications arise, they can be treated immediately and successfully without needing transport of the patient to a different department. Although the incidence of complications may be small it is good to have all equipment available, so that if a problem occurs during a procedure, it is possible to switch to open surgery immediately without delay. The integrated Alphamaquet operating table allows the room to be used as a normal operating room, with the imaging system parked well out of the way.

Developed in parallel with the hybrid operating room, Philips introduced the HeartNavigator. This is a software solution for routine use, significantly increasing the range of indications. It provides greater accuracy and safety, resulting in faster and easier planning of TAVI procedures. The HeartNavigator is still under development, as part of the close collaboration between Philips and our clinic, but it has already been evaluated in over a hundred patients, where it has proved its value in clinical practice. In fact, our present routine would be unthinkable without it.

▲ Figure 2. Plan of the hybrid operating room. The ceiling-suspended X-ray system can be parked well away from the operating table when not in use.

Because it provides accurate measurements, the HeartNavigator provides an objective standard for planning and performing the procedure, rather than relying on the subjective judgment of the operator. It helps in the selection of the appropriate size and type of valve, and ensures accurate positioning.

Hybrid team

Working in the hybrid operating room requires an interdisciplinary team comprising cardiology, heart surgery, anesthesiology, and ancillary staff including a cardiac technician who operates the HeartNavigator system and the heart/lung machine. It is important to have a dedicated team who are used to working closely together. This ensures the fast reactions needed for efficient treatment. In fact, we say that the hybrid operating room requires a hybrid team.

Sterility

The hybrid OR needs to meet the highest standards of sterility, including a laminar air flow ceiling. This places certain demands on the imaging system, which has to be installed in such a way that it is easy to clean and does not interfere with the air flow. The hybrid OR fully meets all sterility requirements of an open OR.

Other applications

In principle, our hybrid OR could be used for other applications, but at present it is used 100% for transcatheter aortic heart valve implantation (TAVI), although this is sometimes done in combination with other catheter procedures. There is also provision for combined valve implantation/bypass surgery, but there has been no demand to date.

Legal requirements

The German healthcare authorities have strict legal requirements for performing interventional heart valve implantation. The surgeons and cardiologists have to have performed a large number of interventions under supervision in order to acquire the necessary experience and expertise.

The imaging system

Mobile C-arms may be adequate for depicting larger stents and catheters, but do not provide the image quality and tube capacity needed for complex cardiovascular procedures. For these reasons, experts recommend the use of fixed C-arms [2].

The hybrid OR at the Klinik für Herzchirurgie, Karlsruhe, is equipped with a Philips Allura Xper FD20 imaging system with an integrated Maquet surgical table. This system has a large-area flat panel detector, which not only provides far higher image quality than an image intensifier system, but also eliminates geometric distortion at the periphery of the image field. This means that accurate measurements can be made anywhere in the image.

Motorized movements with joystick control and automated positioning put the X-ray system under the user's direct control, which is faster and more efficient than relying on an assistant operating a mobile system.

The system is ceiling-mounted, with custom-built ceiling rails that keep the running parts out of the operating field, and do not interfere with the laminar airflow. The system can be positioned anywhere around the operating table (Figures 3, 4), allowing free access to the patient for both transfemoral and transapical procedures.

The rails run almost the complete width of the room, and two-thirds of the length, allowing the system to be parked well away from the operating table when not in use. This eliminates a problem encountered with some systems, in particular bulky floor-mounted systems, where the parking position at the head of the table interferes with the anesthesiologist and the anesthesia equipment.

The flexibility of the Allura Xper FD20 system also makes it suitable for other techniques envisaged for the near future, such as the introduction of aortic stent grafts.

For a surgeon, performing interventions under X-ray control represents a major change in working methods. Instead of working directly with one's hands one has to learn to work by remote control. There are no short cuts: you simply have to learn it if you are going to work in a team with a cardiologist. On the other hand, the Allura Xper FD20 is very user-friendly. It is easy to learn and easy to work with.

The operating table

The Allura Xper FD20 is used in conjunction with a full-specification Maquet surgical table. The designers of the room worked closely with Maquet to ensure that the table is fully integrated with the imaging system, including the Philips BodyGuard collision protection system, without compromising the requirements for surgery.

Lights, monitors, and other devices

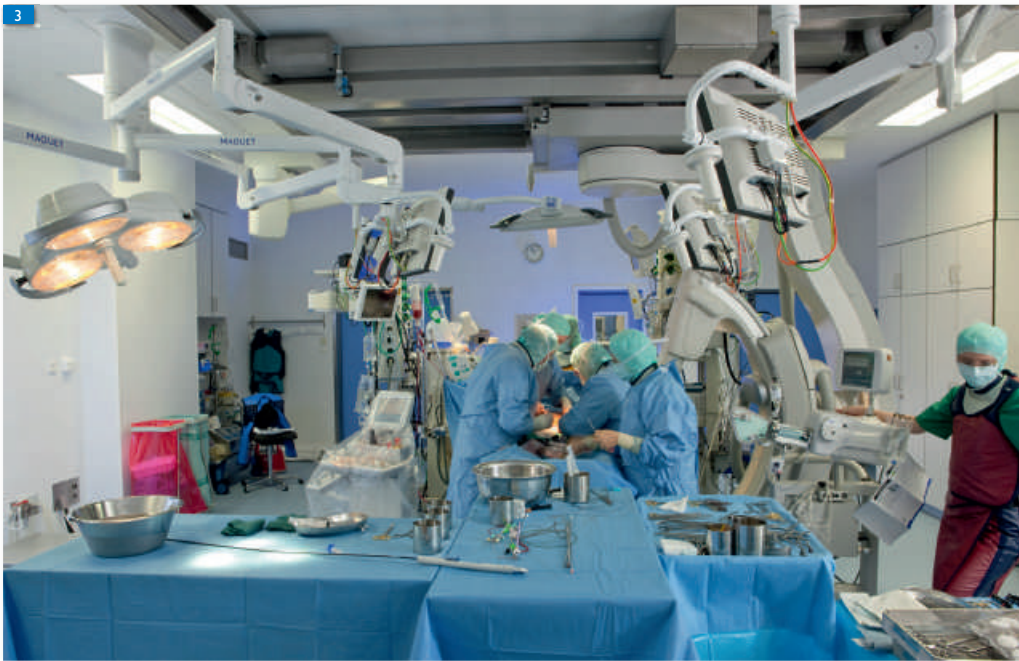All lights, monitors and other devices are mounted on long, articulated booms, giving maximum freedom of positioning without interfering with the laminar air flow.

Valve implantation

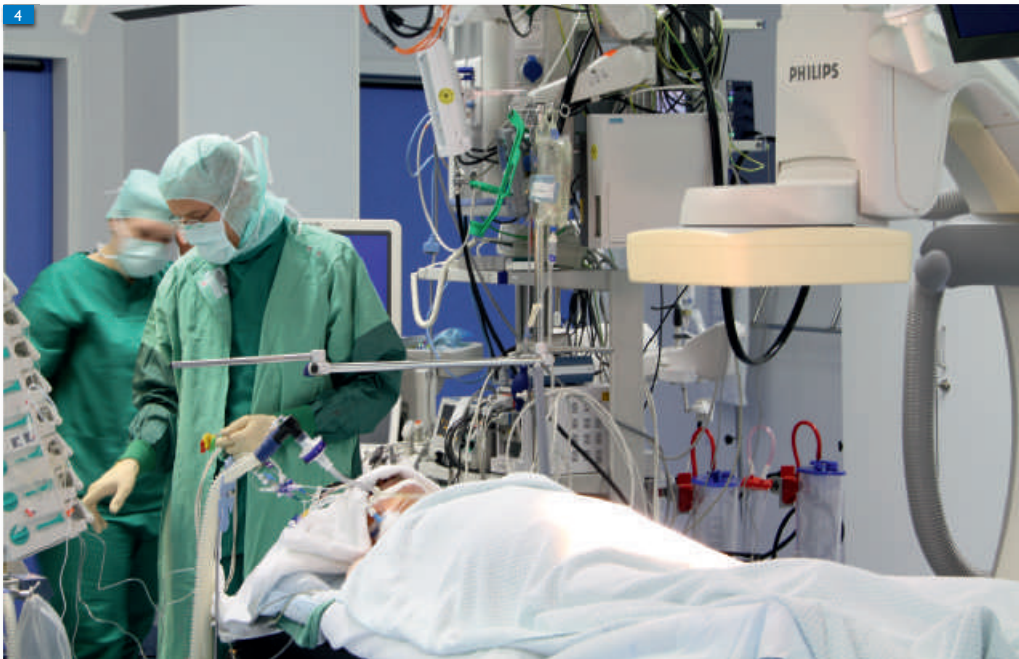Both transapical and transfemoral approaches are used for transcatheter valve implantation (TAVI), depending on the clinical indications and the patient's anatomy. The transfemoral approach has the advantage

► **The hybrid OR fully meets all the sterility requirements of an open OR.**

► **Mobile C-arms do not provide the image quality and tube capacity needed for complex cardiovascular procedures.**



◀ Figure 3. Position of equipment and staff for transfemoral approach



◀ Figure 4. Imaging system in standby position during preparation for anesthesia.

of being a little less invasive but is not feasible in all patients. At our institute procedures are performed approximately 55% transfemoral and 45% transapical. Both access approaches are performed on a beating heart without the need for heart-lung machine. The number of TAVI procedures has increased rapidly, with an estimate of some 8000 procedures performed worldwide in 2009, which was the first full year of commercial availability of the transcatheter valve devices in most of Europe. To date around 550 TAVI procedures have been performed at our institution of which 75% with the Edwards Sapien valve and 25% with the Medtronic CoreValve.

However, TAVI demands the highest possible image quality and accurate navigation. One of the most

critical phases of the procedure is the final positioning of the device prior to deployment. Incorrect positioning may lead to the device being dislodged, or failing to function correctly, which would require correction by open surgery.

Accurate positioning of the device demands correct alignment of the X-ray system with the valve plane, and perpendicular to the device. Even a slight misalignment can cause foreshortening, and may lead to errors in judging the correct location of the device with respect to the valve plane. The optimal view for the device placement should also show the origins of the left and right coronary arteries, without overlap from the coronary sinus, because they must not be occluded by the implanted device.

▶ **TAVI demands the highest possible image quality and accurate navigation.**

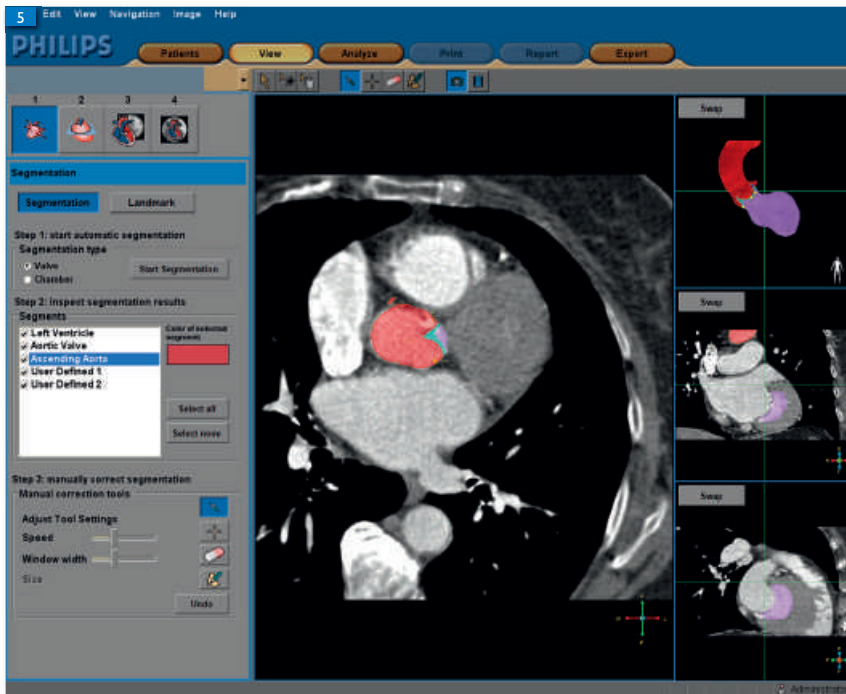


Figure 5. Segmentation: transverse view.

Due to variations in the individual aortic root anatomy it is sometimes difficult to find the correct view, so that the search process might involve as many as 20 X-ray acquisitions in different views to arrive at the proper angulation and rotation. This not only costs time but also means additional radiation exposure for the patient, physician and other staff. To assist in planning and positioning, a new tool known as the HeartNavigator (Philips Healthcare, Best, the Netherlands) is under development that allows planning of optimal X-ray views before the start of the procedure, and provides live guidance during the procedure.

HeartNavigator

The HeartNavigator system is currently being evaluated in our clinic, but has already been shown to provide a real benefit. It is very easy to find the correct plane showing all three cusps of the aortic valve, and to align the imaging system accordingly. Consequently, the working procedure is much faster and the fluoroscopy times are correspondingly shorter, resulting in less radiation exposure and the use of less contrast agent.

Planning the procedure with the HeartNavigator is almost entirely objective, rather than the conventional subjective judgment we used in the past, so that even less experienced staff can perform safe and accurate planning.

Three years ago, TAVI was still in the realms of investigation and research, but has now become a widely accepted procedure in Europe. HeartNavigator helps to integrate TAVI in the clinical routine. The initial planning takes a little time, but this is more than compensated for by the faster procedure and greater accuracy.

Pre-operative CT angiography data are entered into the system on the day before the planned procedure. The CT data are automatically segmented to identify the aortic root, coronary ostia, the aortic valve, the left ventricle and the valve plane running through the bottom of the three cusps (Figure 5).

The segmentation results can be inspected and corrected if necessary. After segmentation the required X-ray projections are planned by positioning a simulated X-ray view that is based on a 3D rendering of the CT data with the same perspective as that of the X-ray system. Views are automatically locked to be in line with the valve plane. The planned views are then stored for use during the procedure.

A major advantage of the HeartNavigator is the ability for the physician to perform precise measurements.

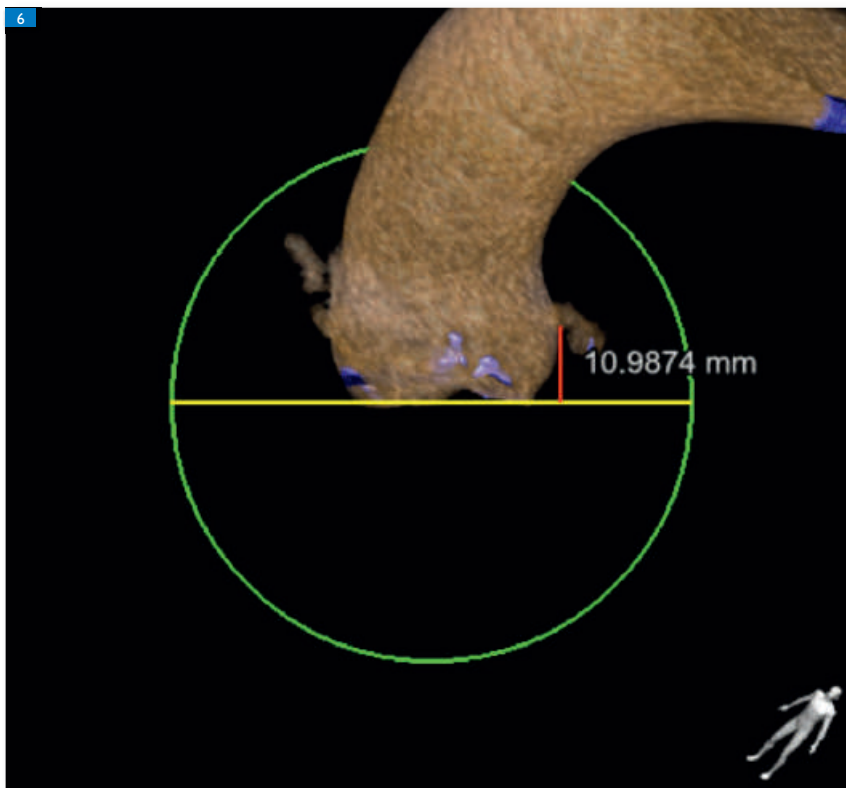


Figure 6. Measurement of distance between valve plane and left coronary ostium. This can affect the choice of valve, but can also influence the choice of procedure by showing the distance between the annulus of the valve and the origins of the coronary arteries. This is a critical factor, in order to ensure that the replacement valve does not occlude the opening of one or the other coronary artery. As a rule of thumb, patients in whom the opening of one of the coronary arteries is less than 10 mm from the annulus of the valve are regarded as unsuitable for the TAVI procedure. However, because the measurements via the HeartNavigator are more accurate than those on the CT images, it has been possible to treat patients who would have been excluded on the basis of the CT images alone.

The manual measurements are greatly facilitated by the automatic detection of the valve plane (Figure 6), which ensures that measurements are performed without foreshortening.

Planning the procedure

Four views are displayed showing the segmented CT data from different viewpoints. Point-to-point measurements can be performed in any of the views, and an appropriate valve can be selected from a library of valve types and dimensions (Figure 7).

Live guidance

During the procedure, the planned views can be recalled and the X-ray system moves automatically to the planned projection. A 3D rendering of the CT data is displayed with the same perspective as the X-ray system and any rotations of the X-ray system are automatically followed by the CT rendering.

After the views have been selected, the C-arm can be automatically steered to the planned views without needing angiography. The CT data and the live fluoroscopy are registered, and the CT image is overlaid on the live fluoroscopy image (Figure 8). To register the CT data to the X-ray system, two short acquisitions are needed from different angles. The registration can be easily performed by the physician at tableside using a touch screen with a sterile cover.

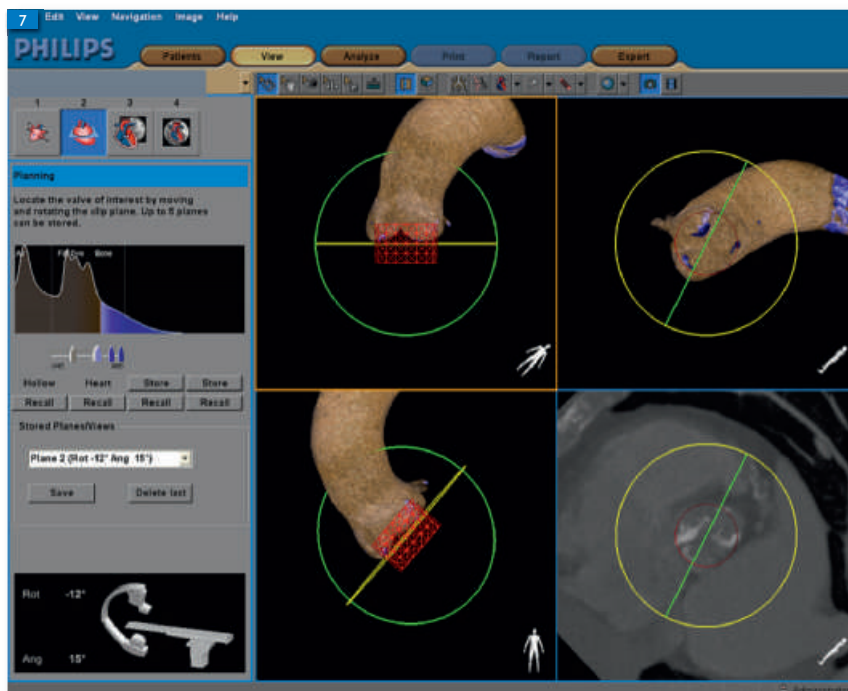
The fused overlay visualization shows the relation between the device as seen on X-ray with the anatomy as seen on CT. The rendering of the CT data shows only the outline of the aortic root (red line) to avoid interference with the X-ray image.

Case study

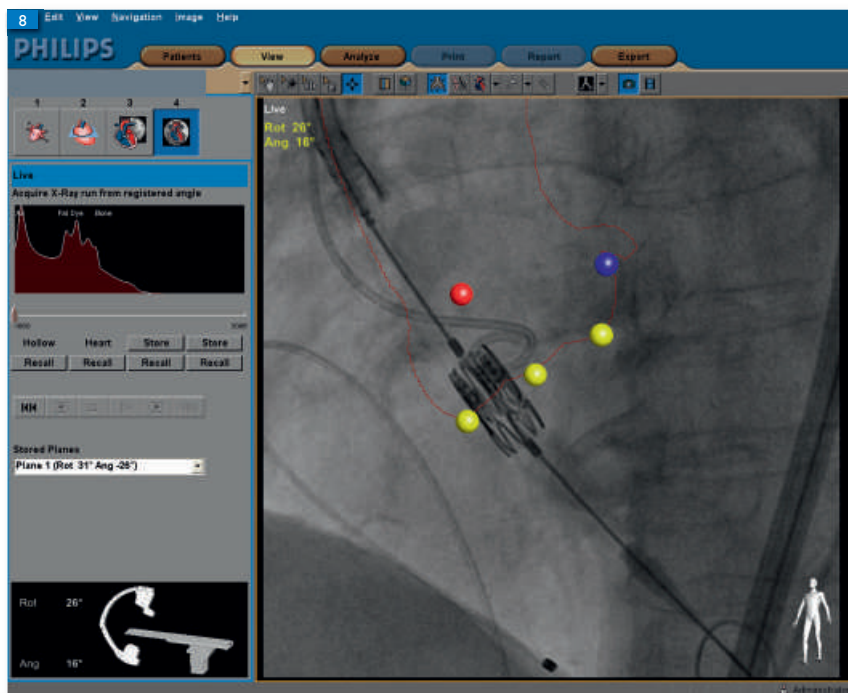
A 76-year old female patient presented with severe calcified aortic stenosis grade III, leading to valve insufficiency (indicated by echocardiography). Following a previous infarction she had been treated for triple vessel disease by multiple bypass surgery, and had received a biventricular pacemaker implantation for AV-block type II.

At the time of presentation the patient was suffering from hypertension, diabetes IIb, carotid artery stenosis, and slightly limited left-ventricular function (60% ejection fraction).

Discussion by the interdisciplinary heart team concluded that the patient was not a suitable candidate for open surgery due to severe comorbidities, associated with a high surgical risk (Euroscore 34.5). The patient was referred for TAVI and, based on CT screening of the iliac vessels, a transapical approach was selected. To prepare for the procedure, HeartNavigator



▲ Figure 7. Planning the procedure. The green circle represents the view from the X-ray system and the yellow circle is perpendicular to the green circle. The view can be changed using the Rotation Interactor. The C-arm orientation indicator shows the system angulations corresponding to the top-left view. In the 3D volume rendering of the CT aortic root, calcifications are automatically shown in blue. The red mesh indicates the planned device.



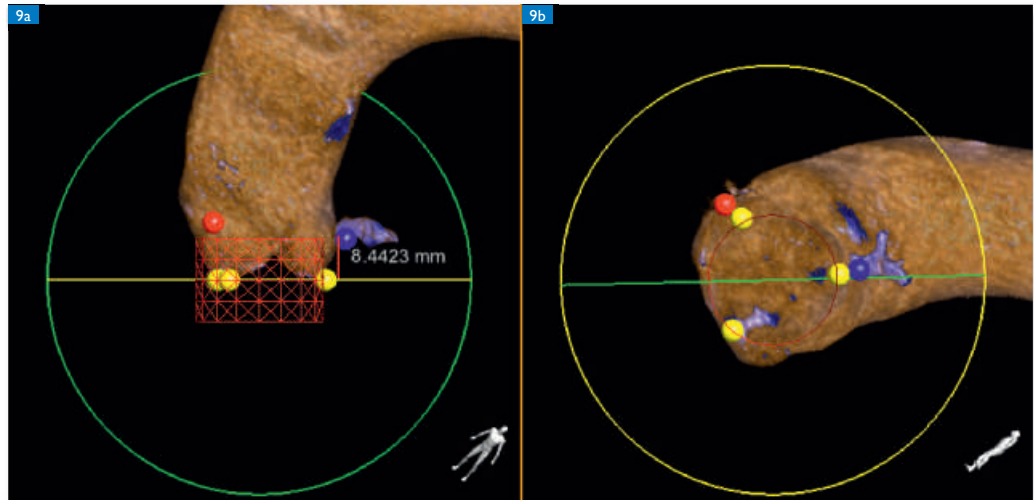
▲ Figure 8: Overlay of CT outline (red line) on live fluoroscopy. The three yellow landmarks indicating the bottom of the cusps are in line, indicating that the X-ray view is in line with the valve plane. The blue marker indicates the ostium of the left coronary artery and the red marker indicates the ostium of the right coronary artery.

▶ Figure 9. Planning with HeartNavigator.

Figure 9a. Planned optimal X-ray view showing the ostium of the left coronary artery with distance measurement between the coronary artery and the valve plane.

The blue marker indicates the ostium of the LCA, the red marker indicates the ostium of the RCA, and the yellow marker indicates the bottom of the cusps. The virtual 23 mm valve, shown in red, fits within the anatomy.

Figure 9b. View perpendicular to the planned view showing the viewplane (green line) running through the LCA.



viewplanning was performed, based on the pre-operative CTA. The software automatically segmented the left ventricle, the aortic valve and the aorta, including the coronary ostia. Measurement showed a short distance between the ostium of the LCA and the valve plane of only just over 8 mm. The HeartNavigator automatically calculated views in line with the valve plane. The optimal X-ray view was determined, showing the origin of the left coronary artery: 10° LAO, 25° Cranial. This view was stored to be used during the procedure.

Virtual device implantation with the HeartNavigator (Figure 9) confirmed the choice of the 23 mm valve size, which had previously been indicated by the ultrasound examination. After transapical access, the X-ray system was automatically positioned in the planned 10° LAO, 25° Cranial view at the touch of a button. By planning the view beforehand, based on the CTA, we avoided the need to make several aortic root angiograms to find the optimal X-ray view for this specific patient anatomy. In this way, the positioning could be performed without using any contrast agent or additional radiation exposure.

After registration, the HeartNavigator provided an overlay image showing the fluoroscopy in relation to the outline of the aortic root derived from the CTA. Balloon dilatation was performed prior to inserting the valve (Figure 10). An Edwards Sapien XT 23 mm valve was inserted and positioned under fluoroscopy (Figure 11). Although the HeartNavigator overlay provided approximate guidance for positioning, its accuracy is limited by the motion of the heart, due to the lack of dynamic motion compensation.

After correct positioning had been confirmed with a final angiogram, the valve was implanted under rapid pacing at 200/min. Checkup angiography showed

good positioning of the valve with respect to the left coronary ostium but also showed a severe paravalvular leak grade I-II (Figure 12). Balloon post-dilatation resulted in a good result with no significant residual leak (grade 0-I) (Figure 13).

Treatment resulted in marked reduction of valve insufficiency and the patient was without adverse events at two months postoperatively.

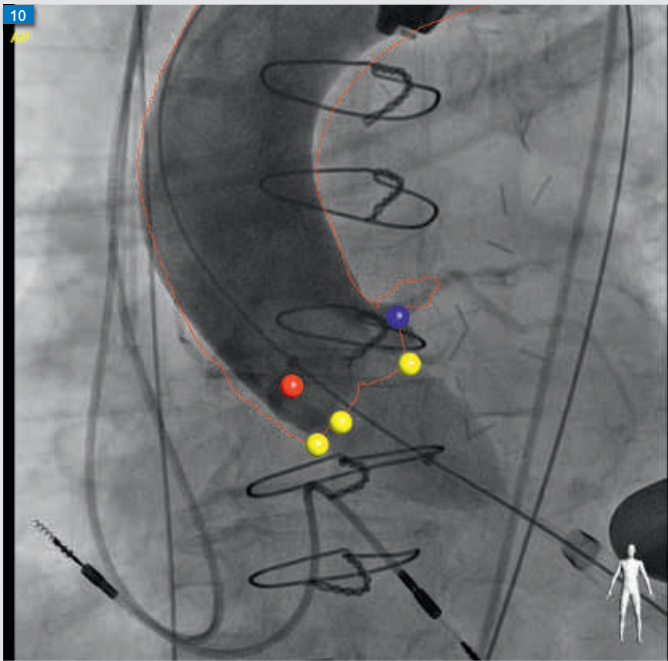
Conclusion

Interventional techniques for aortic valve implantation offer important advantages over open heart surgery, particularly in older and critically ill patients who are unsuitable candidates for open surgery. Both transapical and transfemoral approaches may be used, depending on the clinical indications and the patient's anatomy.

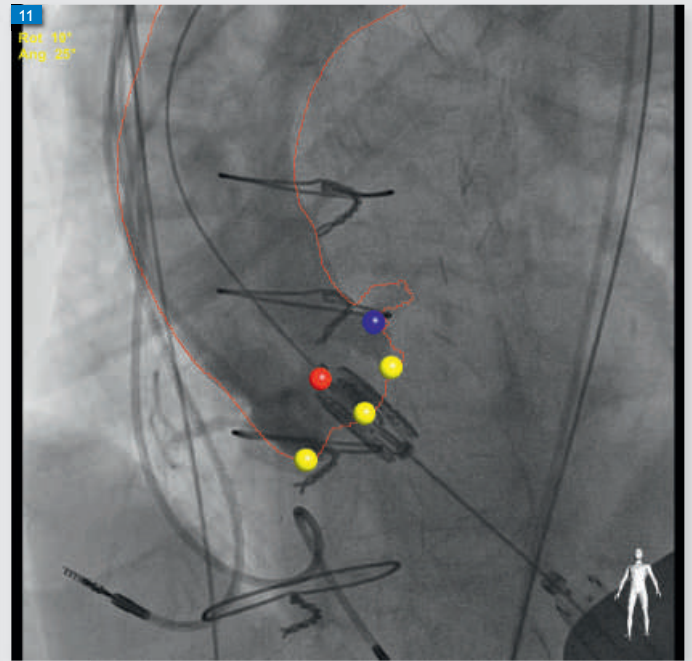
Transcatheter Aortic Valve Implantation (TAVI) has the advantage of being minimally invasive, but demands the highest possible image quality and accurate navigation. These demands are often beyond the capacity of a mobile surgical C-arm system but, on the other hand, a conventional cath lab would not meet all of the requirements for surgery, particularly with respect to sterility.

For this reason, we opted for a “hybrid” operating room, with a fixed high-end imaging system, enabling interventional techniques and open surgery to be performed in the same location. To assist in procedure planning and navigation, a new tool known as the HeartNavigator (Philips Healthcare, Best, the Netherlands) is used that allows planning of optimal X-ray views and device size before the start of the procedure, and provides live guidance during the procedure ■

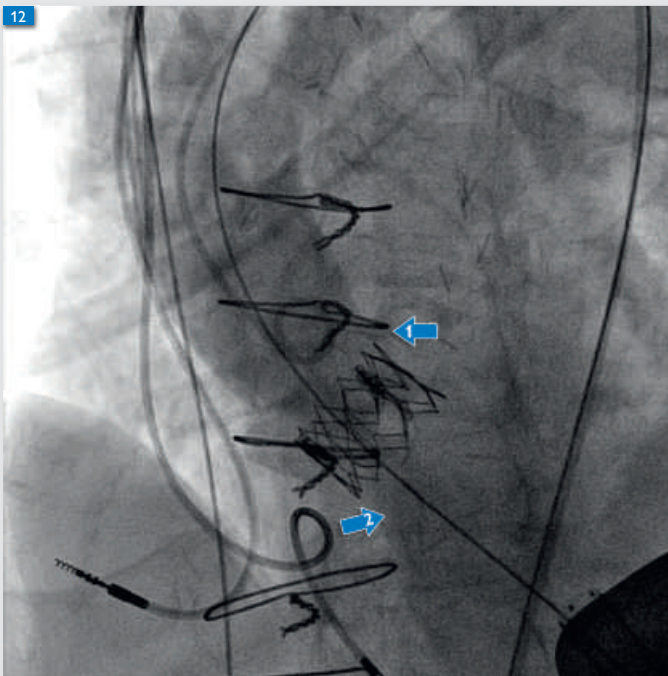
▶ **Interventional techniques for aortic valve implantation offer important advantages over open surgery.**



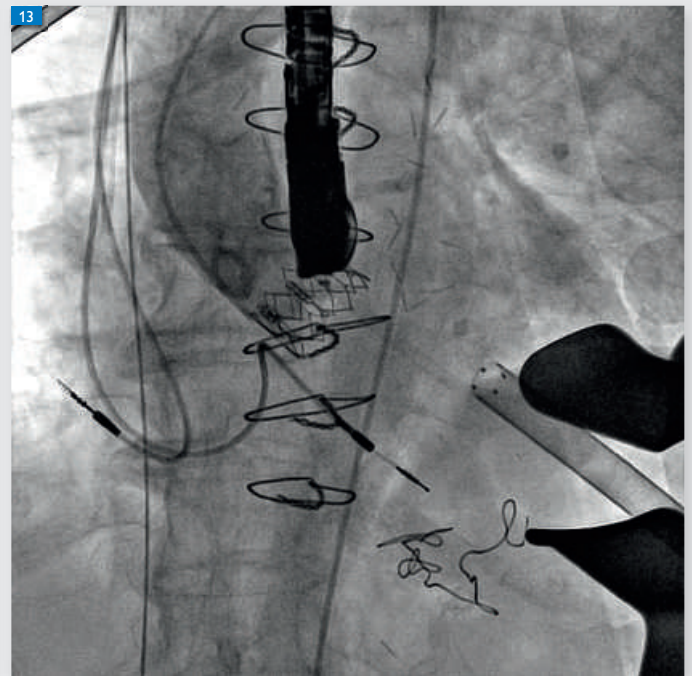
▲ Figure 10. HeartNavigator overlay during balloon deployment. Red outline marks the aortic root derived from the CTA



▲ Figure 11. HeartNavigator overlay during final positioning of the valve.



▲ Figure 12. Angiography after initial valve deployment. Arrow 1 indicates sufficient distance between offspring of the LCA and the valve device. Arrow 2 paravalvular leak.



▲ Figure 13. Angiography after balloon post-dilatation showing no residual paravalvular leak.

References

[1] Benjamin ME. *Building a Modern Endovascular Suite*. Endovascular Today. 2008; 3: 71-78.

[2] Bonatti J, Vassiliades T, Nifong W, et al. *How to Build a Cath-Lab Operating Room*. Heart Surg Forum. 2007; 10: E344-348.

**Philips Healthcare is part of
Royal Philips Electronics**

How to reach us

www.philips.com/healthcare
healthcare@philips.com

Asia

+49 7031 463 2254

Europe, Middle East, Africa

+49 7031 463 2254

Latin America

+55 11 2125 0744

North America

+1 425 487 7000

800 285 5585 (toll free, US only)

HeartNavigator is not yet available in US and Canada

Please visit www.philips.com/heartnavigator



© 2010 Koninklijke Philips Electronics N.V.
All rights are reserved.

Philips Healthcare reserves the right to make changes in specifications and/or to discontinue any product at any time without notice or obligation and will not be liable for any consequences resulting from the use of this publication.

Printed in The Netherlands.
4522 962 67821 * DEC 2010