

Safety and Efficacy of Dual-Axis Rotational Coronary Angiography Vs. Standard Coronary Angiography

Andrew J. Klein,¹ MD, Joel A. Garcia,¹ MD, Paul A. Hudson,¹ MD, Michael S. Kim,¹ MD, John C. Messenger,¹ MD, Ivan P. Casserly,¹ MB, BCh, Onno Wink,² PhD, Brack Hattler,³ MD, Thomas T. Tsai,³ MD, MSc, S.Y. James Chen,¹ PhD, Adam Hansgen,¹ BS, and John D. Carroll,^{1*} MD

Objective: To determine the safety and efficacy of dual-axis rotational coronary angiography (DARCA) by directly comparing it to standard coronary angiography (SA). **Background:** Standard coronary angiography (SA) requires numerous fixed static images of the coronary tree and has multiple well-documented limitations. Dual-axis rotational coronary angiography (DARCA) is a new rotational acquisition technique that entails simultaneous LAO/RAO and cranial/caudal gantry movement. This technological advancement obtains numerous unique images of the left or right coronary tree with a single coronary injection. We sought to assess the safety and efficacy of DARCA as well as determine DARCA's adequacy for CAD screening and assessment. **Methods:** Thirty patients underwent SA following by DARCA. Contrast volume, radiation dose (DAP) and procedural time were recorded for each method to assess safety. For DARCA acquisitions, blood pressure (BP), heart rate (HR), symptoms and any arrhythmias were recorded. All angiograms were reviewed for CAD screening adequacy by two independent invasive cardiologists. **Results:** Compared to SA, use of DARCA was associated with a 51% reduction in contrast, 35% less radiation exposure, and 18% shorter procedural time. Both independent reviewers noted DARCA to be at least equivalent to SA with respect to the ability to screen for CAD. **Conclusion:** DARCA represents a new angiographic technique which is equivalent in terms of image quality and is associated with less contrast use, radiation exposure, and procedural time than SA. © 2011 Wiley-Liss, Inc.

Key words: coronary angiography; rotational coronary angiography; dual-axis angiography

INTRODUCTION

Standard angiography (SA) is performed in the majority of catheterization suites and entails fixed views with a “step and shoot” approach. Several studies using other modalities including ultrasound, angioscopy, and pathology have demonstrated the limited diagnostic accuracy of SA [1–7]. In an effort to overcome many of these limitations, single-axis rotational angiography (RA), wherein at a minimum 360° different gantry images (three rotations of 120° of acquisition each) of the coronary tree are obtained instead of the standard fixed 6–11 images, was developed. This rotational acquisition method was subsequently shown to be safer than SA [8–10] and the image content to be comparable [9]. There are limitations of single-axis RA including the fixation of the cranial/caudal angulation necessitating at least two gantry rotations (one cranial and one caudal) for a complete assessment of the left coronary artery (LCA). Additionally, the cranial angulation (25°) that is commonly used during RA is not concordant with the desire of many operators for steeper cranial angulations, especially for the evaluation of the left anterior descending artery. These limitations and the quest for a visually superior and safer angiographic evalua-

tion have led to the development of dual-axis rotational coronary angiography (DARCA).

¹Division of Cardiology, University of Colorado Denver, Anschutz Medical Campus, Aurora, Colorado

²Philips Healthcare, Clinical Research, Anschutz Medical Campus, Aurora, Colorado, Denver, Colorado

³Division of Cardiology, Denver VA Medical Center, Denver, Colorado

Conflict of interest: John D. Carroll, MD and S.-Y. James Chen, PhD are co-inventors of patented 3D vascular modeling software assigned to the University of Colorado Denver and University of Chicago that has been licensed to Philips Healthcare, but was not used in this study. Dr. Carroll is a consultant and speaker for Philips Healthcare. Onno Wink, Ph.D. is an employee of Philips Healthcare. All other authors have no conflicts of interest.

*Correspondence to: John D. Carroll, MD, Professor of Medicine, Division of Cardiology, University of Colorado Denver, Campus Box 132, 12401 East 17th Avenue, Aurora, CO 80045.
E-mail: John.Carroll@ucdenver.edu

Received 7 June 2010; Revision accepted 27 August 2010

DOI 10.1002/ccd.22804

Published online 11 March 2011 in Wiley Online Library (wileyonlinelibrary.com)

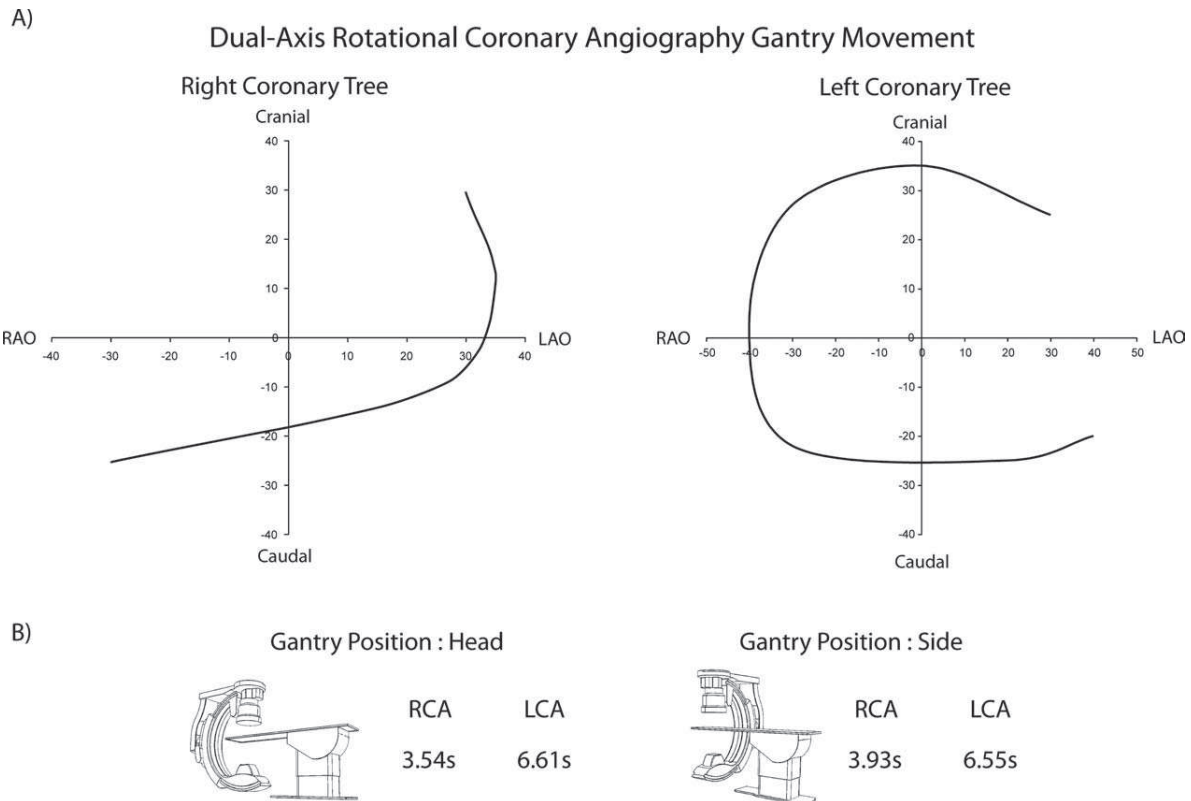


Fig. 1. (A) Dual-axis rotational coronary angiogram gantry sweeps for both the right and left coronary tree. (B) Gantry position time differences: the gantry for DARCA can be placed in either head position (HP) or side position (SP). Each position is associated with different gantry sweep speeds. This necessitates an adjustment in the prolonged coronary injection required for complete vessel opacification throughout the DARCA acquisition. DARCA = dual-axis rotational coronary angiogram.

DARCA permits complete off-axis rotational visualization of the coronary tree with a single injection. DARCA is a novel acquisition method wherein the gantry automatically swings in a trajectory involving a constantly changing left anterior oblique (LAO)/right anterior oblique (RAO) rotation and cranial/caudal angulation permitting complete visualization of the right or left coronary artery with a single injection. (Fig. 1A) The DARCA gantry trajectory was designed to encompass all of the standard traditional views that are commonly acquired during SA, [11] including gantry positions that “optimally view” all of the major coronary segments. The “optimal views” for a specific coronary segment and/or lesion are those that minimize vessel foreshortening and overlap. These optimal views were defined through a 3D modeling study [12] that determined the gantry positions for each major coronary segment that minimized vessel foreshortening and overlap in a large cohort of patients. To optimize DARCA, these scientifically-based gantry positions were incorporated into the design of the DARCA LCA and RCA tra-

jectories in an effort to hit the “hot spots” for each coronary segment thus minimizing imaging inaccuracies.

While the safety and efficacy of single-axis RA has been well documented [8–10,13,14], there are no systematic evaluations of DARCA as compared to SA. We sought to compare the safety and efficacy of DARCA to SA with respect to use of total contrast volume, radiation dose and procedural time. Additionally, we sought to assess the ability of DARCA to screen for coronary artery disease (CAD).

METHODS

Patient Population

This study was approved by the Colorado Institutional Review Board (COMIRB). We enrolled 30 consecutive patients scheduled for diagnostic coronary angiography at the Denver Veterans Affairs Hospital. Written informed consent was obtained from each patient. Inclusion criteria were age >18 years, ability, and willingness to provide informed consent, and an

indication for diagnostic coronary angiography to evaluate possible CAD. Exclusion criteria included presence of an acute coronary syndrome, known allergy to iodinated contrast, renal insufficiency ($>1.5 \text{ mg dl}^{-1}$), prior coronary-artery-bypass-graft (CABG), and inability to provide informed consent.

The contrast agent used was Iodixanol (Visipaque®-GE Healthcare, Cork, Ireland) and all injections (SA and DARCA) were performed using an Acist Voyager® power injection system (Acist Medical Systems, Minneapolis, MN) at a flow rate no greater than $2.5 \text{ cm}^3 \text{ sec}^{-1}$ for a total of 18 cm^3 or less for the left coronary system and no greater than $2.5 \text{ cm}^3 \text{ sec}^{-1}$ for a total of 10 cm^3 or less for the right coronary system through a 6 Fr. catheter. To ensure accurate timing and maximal vessel opacification all DARCA acquisitions using the ACIST Voyager® system were synchronized with the X-ray system.

Angiographic Studies

All angiographic procedures were performed using the femoral approach and the FD20 Philips digital X-ray system (Philips Healthcare, Best, The Netherlands). The DARCA trajectories designed by the investigators and assessed in this study are shown in Fig. 1. All catheterization laboratory operators were experienced and board certified invasive or interventional cardiologists trained in RA. Patients were positioned, prepared, and draped in the typical fashion for a diagnostic coronary angiogram with arms at their sides.

Angiographic Acquisitions

Standard angiography. Patients first underwent SA of either the left or right coronary system followed by DARCA. The SA protocol consisted of four angiographic views of the LCA using the traditional four gantry angles (LAO-cranial, LAO-caudal, RAO-cranial, RAO-caudal) and two images of the RCA (LAO and PA-cranial or RAO) with a 15 frame per second acquisition rate. The specific gantry angles chosen, collimation, and the magnification, i.e., field of view (FOV) settings were per the operator's discretion to best optimize coronary visualization. The FOV used for SA and/or DARCA was either 8-in. or 13-in. If a chronic total occlusion (CTO) of the right coronary tree was discovered on SA or a nondominant RCA present or catheter dampening occurred, use of DARCA for the RCA was left to the operator's discretion.

Dual-axis rotational coronary angiography. Following SA of either the left or right coronary system, careful iso-centering in postero-anterior and $45\text{--}60^\circ$ LAO views was performed as it is standard in RA [8,10,14]. The time to perform iso-centering was

included in the DARCA total time. The FOV was then chosen by the operator and was 8-in. (for both the left and right coronary trees) in the majority of cases ($>80\%$), thus providing operators similar image magnification as static SA. As DARCA is an automated acquisition, the gantry was then set to the prespecified end and start positions (Fig. 2) for the respective coronary tree. Following final confirmation of a synchronized contrast injection, cineangiography was performed by depressing the pedal. DARCA acquires images at a rate of 30 frames per second.

The ability to completely visualize an entire coronary tree during one injection requires both a highly mobile gantry and a prolonged coronary injection of contrast. The mobility of the rotating gantry is dependent upon the position of the X-ray system and the system can either assume a head position (HP) or a side position (SP; Fig. 1B). Given the physics of the moving gantry, depending upon the position of the system, the time required for a complete DARCA trajectory varies (Fig. 1B). All DARCA acquisitions in this study were performed from the "head position" of the gantry as this requires less time with a shorter injection.

The time required for a DARCA averages 6.7 and 3.96 sec for the left coronary arteries (LCA) and right coronary artery (RCA), respectively and thus is most conveniently performed via an automated power injection system to insure a constant rate of contrast delivery throughout the acquisition. These prolonged injections have previously been shown to be safe [15].

Data Collection and Study Endpoints

Safety analysis. Patient demographics, risk factors, and procedure data were collected in a prospective standardized manner. The primary endpoints for this study included the total amount of contrast media used, radiation exposure, and time required to complete the angiographic study with each modality.

For SA, only after selective engagement of either the left main or the RCA, were the values for contrast, radiation, and time recorded. For DARCA, contrast use and time was recorded from the time of the start of the iso-centering process. The time, radiation and contrast required to engage the coronary ostia, exchange catheters, and perform noncoronary angiography was excluded from the analysis for both arms equally. Fluoroscopy, cineangiography, and total radiation dose were directly recorded from the imaging systems as a dose area product (DAP).

The safety of the prolonged coronary injection during DARCA was also evaluated via the invasive measurement of a pre and post-DARCA injection blood pressure measurement. Heart rate was assessed pre and postinjection by use of continuous ECG monitoring.

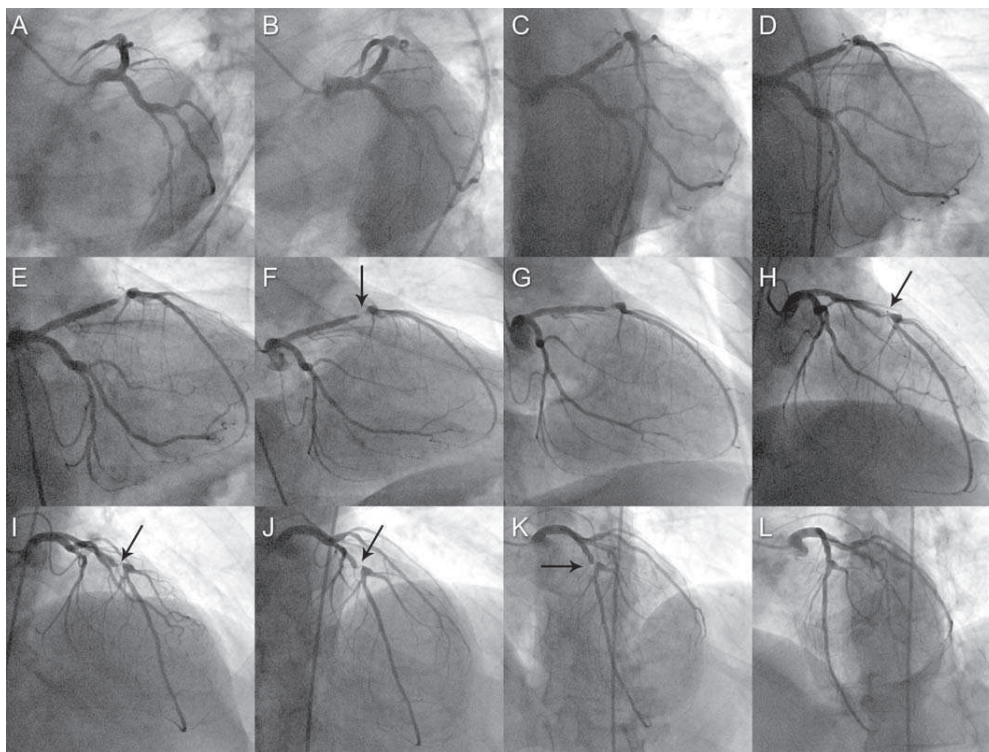


Fig. 2. Dual-axis rotational coronary angiography: a single prolonged injection of the left coronary tree is displayed starting from LAO Caudal (A) and ending at LAO cranial (L). Note the critical LAD stenosis (arrow) which is present in numerous images. LAO = left anterior oblique; LAD = left anterior descending.

All adverse events, arrhythmias, and/or symptoms observed by the physician or reported by the patient were also recorded.

Image content analysis. To compare the image quality and CAD screening adequacy of DARCA, all studies were reviewed by two independent invasive cardiologists. The reviewers were asked to identify the number of coronary artery stenoses with a $>50\%$ diameter reduction as visualized on both SA and DARCA. The total number of stenoses identified was compared between the two types of image acquisitions and between reviewers. In addition each reviewer completed a Likert scale assessment (score range 0–10) comparing the screening adequacy of the two different acquisition types for each subject.

Statistical Analysis

Comparisons of contrast dose, radiation exposure and time between SA and DARCA were performed using a Student's *t* test. Categorical variables are expressed as percentages. Continuous variables are expressed as a mean and standard deviation. Results were considered statistically significant at a $P < 0.05$.

The statistical analysis was performed using Xcel standard analysis (Microsoft Systems, Redford, WA) and SAS version 9.1 (Cary, NC).

RESULTS

Patient Characteristics

The majority of patients were male (97%), had a history of smoking, hyperlipidemia, and hypertension (Table I). Of the patients enrolled, 21 (70%) had evidence of lesions $>50\%$ by angiography. Thirty left coronary trees and 21 right coronary trees were imaged with both DARCA and SA (Fig. 2). Nine right coronary arteries were not assessed using DARCA at the operators discretion secondary to small vessel/nondominance ($n = 3/30$), chronic total occlusion ($n = 3/30$), or significant catheter dampening ($n = 3/30$).

Contrast

For the 21 patients who underwent DARCA and SA of both the LCA and RCA, contrast utilization was significantly less with DARCA (27.3 ± 4.6 vs. 52.9 ± 11.7 ml; $P < 0.0001$). Similarly, in those nine patients who

TABLE I. Demographics

	N (%)
Male	29 (96.67%)
Hypertension	23 (76.67%)
Diabetes mellitus	4 (13.33%)
Hyperlipidemia	25 (83.33%)
Known CAD	12 (40%)
Prior PCI	9 (30%)
Tobacco history	19 (63.33%)

This study enrolled a total of 30 patients with the aforementioned comorbidities.

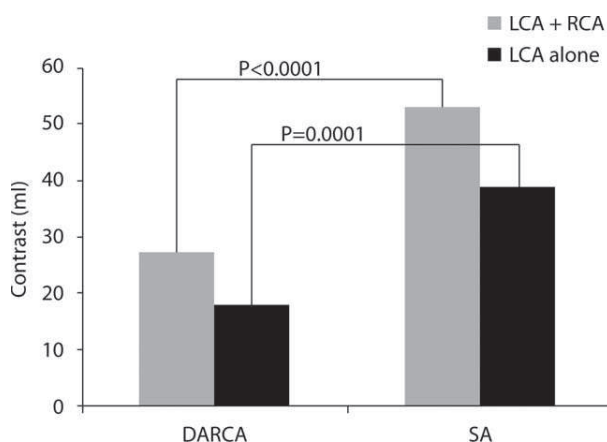


Fig. 3. Contrast utilization: average contrast load for DARCA compared to SA is displayed for the 21 patients who received both left and right coronary evaluations with both modalities as well as those nine patients wherein only LCA angiography was performed with both modalities. DARCA = dual-axis rotational coronary angiogram; SA = standard angiography.

underwent DARCA evaluation of the LCA only, there was a significant reduction in contrast use when compared to SA (17.9 ± 2.3 vs. 38.8 ± 14.9 ml; $P = 0.001$) (Fig. 3) Overall, there was a mean 51% reduction in mean contrast media used with DARCA versus SA.

Radiation

The total DAP reported for DARCA was significantly less than SA in those patients ($n = 21$) who had both the LCA and RCA studied (DAP = 23.8 ± 6.2 vs. 38.0 ± 11.5 Gy cm^{-2} ; $P \leq 0.0001$) and those ($n = 9$) who only had the LCA evaluated with both techniques (DAP 13.4 ± 5.4 vs. 23.3 ± 7.6 Gy cm^{-2} ; $P \leq 0.0001$) (Fig. 4). When combined, DARCA decreased radiation exposure by an average of 35% as compared to SA.

Time

When both the LCA and RCA were evaluated with each type of angiography, there was a decrease in procedural time (164 vs. 211 sec; $P = 0.003$) that was not

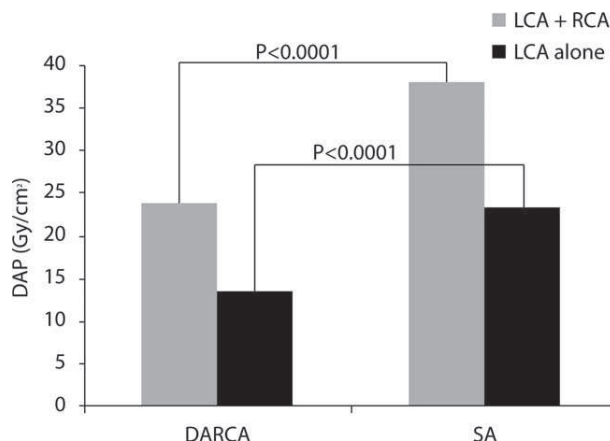


Fig. 4. Radiation exposure: average dose area product (Gy cm^{-2}) for DARCA compared to SA is displayed for the 21 patients who received both left and right coronary evaluations with both modalities as well as those nine patients wherein only LCA angiography was performed with both modalities. DARCA = dual-axis rotational coronary angiogram; SA = standard angiography; LCA = left coronary artery.

seen when only the LCA system was studied. (126.5 vs. 147 sec; $P = 0.242$) (Fig. 5). Overall, DARCA decreased mean procedural time by 18% when compared to SA.

Hemodynamic Effects of Prolonged Injections

For the DARCA injection of the LCA system, the average preinjection mean arterial pressure (MAP) was 81 ± 18 mm Hg. There was a statistically significant decrease in the immediate post injection MAP to 76 ± 17 mm Hg; $P = 0.006$. There was no significant change in heart rate noted (71 ± 15 to 70 ± 14 bpm; $P = 0.229$). During the DARCA RCA injections, there was no significant change in MAP (81 ± 17 to 79 ± 14 mm Hg; $P = 0.127$) nor heart rate (73 ± 14 to 73 ± 15 bpm; $P = 0.5$). Neither symptoms nor arrhythmias were observed or reported during any of the DARCA injections.

Image Content Analysis

Each subject's angiograms were reviewed independently for the presence or absence of lesions $>50\%$ by two reviewers (Table II). Quantitative coronary angiography was not used. Reviewer no. 1 noted an average of 1.6 ± 1.8 lesions on SA and 1.6 ± 1.9 lesions on DARCA ($\kappa = 0.98$). Reviewer no. 2 noted an average of 1.4 ± 1.7 lesions on SA and 1.5 ± 1.8 lesions on DARCA ($\kappa = 0.93$). Combined there was an average of 1.5 ± 1.7 lesions seen on SA and 1.5 ± 1.8 lesions seen on DARCA ($P = 0.5$). The inter-observer variability (Kappa with Confidence intervals) per vessel

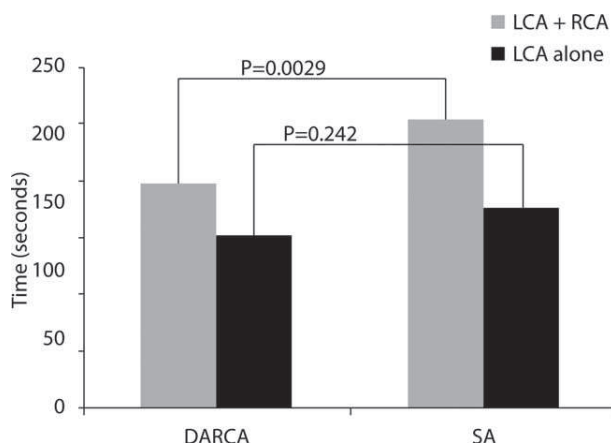


Fig. 5. Procedural time: average procedural time for DARCA compared to SA is displayed for the 21 patients who received both left and right coronary evaluations with both modalities as well as those nine patients wherein only LCA angiography was performed with both modalities. DARCA = dual-axis rotational coronary angiogram; SA = standard angiography; LCA = left coronary artery.

TABLE II. Image Content Analysis

	Number of lesions visualized per modality		Variability
	SA	DARCA	SA vs. DARCA
Reviewer no. 1	1.6 ± 1.8	1.6 ± 1.9	$\kappa = 0.98$ (0.94–1.0)
Reviewer no. 2	1.4 ± 1.7	1.5 ± 1.8	$\kappa = 0.93$ (0.89–1.0)

This table displays the number of lesions greater than 50% visualized on standard angiography (SA) versus dual-axis rotational angiography (DARCA) for both reviewers and the correlation coefficient for each reviewer. The variability was measured by assessing the correlation coefficient of the number of lesions seen on standard angiography versus those lesions seen on DARCA for each reviewer. The inter-observer variability is expressed as the confidence intervals around the kappa.

was: LAD 0.92 (0.89–0.94), Left circumflex: 0.96 (0.91–1.0) and RCA: 1.0 (1.0–1.0). Both reviewers also completed a Likert score assessment of each subject’s angiograms based on acquisition type. The mean Likert score for CAD screening adequacy was 5.2 ± 0.7 (Reviewer no. 1) and 5.6 ± 1.5 (Reviewer no. 2) indicating no difference between SA and DARCA to detect significant coronary stenoses (Fig. 6).

DISCUSSION

DARCA represents a novel acquisition technique for catheter-based rotational coronary angiography and in this study, we found that DARCA can be performed easily, and is associated with less contrast media use, procedural time and radiation exposure while being equal in terms of image content. In addition, the large number of intentionally designed gantry positions

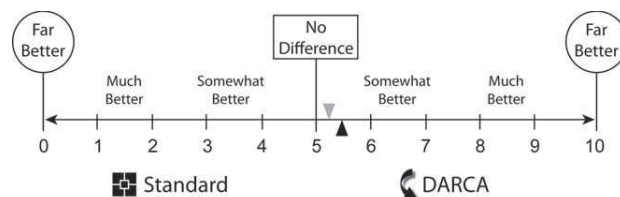


Fig. 6. Coronary artery disease screening adequacy: the Likert scale/score with reviewer no. 1 (gray triangle) and reviewer no. 2 (black triangle) blinded assessment of DARCA’s ability to assess for obstructive CAD showing an equivalence to slight favoring of DARCA over standard angiography. DARCA = dual-axis rotational coronary angiogram; CAD = coronary artery disease.

obtained with DARCA provides the operator with the greatest chances of obtaining coronary artery images with the least degree of foreshortening and overlap; a feature which should translate to being able to choose better working views for coronary interventions.

Improvements in the safety of coronary angiography are a top priority. One potential adverse outcome from coronary angiography is contrast-induced nephropathy (CIN). A critical risk factor for CIN is the volume of contrast administered during angiography, [16–18] and although patients with baseline renal dysfunction were excluded from this study, the extremely low volumes of contrast used during DARCA (mean of 17.9 ± 2.3 and 27.3 ± 4.6 ml for LCA only and LCA + RCA evaluations, respectively) make it an attractive option for patients with renal dysfunction. In fact, when directly compared to SA, DARCA resulted in a 51% reduction in contrast utilization. Further studies in a higher risk CIN population would be warranted to specifically address this issue.

X-ray exposure is another critical safety issue in all catheterization laboratories and for the patient includes their cumulative exposure from all medical sources over a lifetime. X-ray-based imaging technologies as well as the techniques in using them need to be optimized to reduce doses without reducing the imaging goals; DARCA is clearly an important improvement in technique that achieves this enhanced efficiency in radiation use. Similar to single-axis RA, in this study DARCA demonstrated a significant reduction in radiation exposure as directly compared to SA (an average of a 35% reduction) even though SA used an acquisition of 15 frames per second, while the DARCA acquisitions employs a higher rate (30 frames per second) which should lead to a higher radiation dose. For those patients who are referred for coronary angiography, the use of DARCA offers angiography with the lowest possible dose available at this time while delivering comparable angiographic results. Furthermore, as it has been previously shown that single plane RA

(cranial and caudal rotations) reduces staff radiation exposure when compared to SA and DARCA uses only one acquisition, DARCA likely reduces both operators and staff radiation exposure, an advantage in high volume laboratories. Though this will need to be more directly assessed in future studies, this technique would be an advantage in high volume laboratories to improve operator and staff safety [10].

Procedural time is always of concern in busy catheterization laboratories and with any new technique, there is a learning curve which may increase procedural time. This has been cited as the etiology of the neutral effect of RA as compared to SA on this parameter in at least one study [8]. In this study, we actually have demonstrated a 22% significant reduction in procedural time as compared to SA when both the LCA and RCA were evaluated. This finding likely arises from the considerable experience of the operators in this study. Regardless, in today's busy catheterization laboratories, once an initial training period has been completed for those not familiar with RA, DARCA may provide a method to reduce in lab time.

One potential concern with DARCA is the need for a prolonged coronary injection as hemodynamic and arrhythmogenic events have been reported previously during long contrast injections [19]. Our group has recently studied the safety of prolonged coronary injections and noted no clinically significant heart rate or mean blood pressure changes during a 7.2-sec injection [15]. During the current study, we confirmed these results as we noted no clinically significant decreases in either blood pressure or heart rate. It is also noteworthy that DARCA injections are significantly shorter than the one studied in the 7.2-sec injection protocol. It should be noted that the contrast agent used in both studies was isosmolar (iodixanol, i.e., Visipaque®-GE Healthcare, Cork, Ireland) and such a safety profile may not be present if other contrast agents are used.

The ability of a new angiographic technique to adequately assess for the presence or absence of CAD is critical. Though we did not perform a randomized blinded assessment of each angiogram for this purpose, we did address this point. All of the images in our study were independently evaluated by two experienced invasive cardiologists who assessed the number of lesions seen on a segment by segment comparison for both SA and DARCA. The concordance rate between the two types of acquisition as well as between reviewers was excellent with an average of 95% agreement on the presence of lesions between SA and DARCA. Furthermore, both reviewers found that in the majority of cases DARCA was at least equivalent to SA for CAD screening adequacy. These results are consistent with a recently published image content

study [9] that demonstrated RA to be at least comparable if not superior to SA in the screening adequacy and lesion assessment of CAD.

There are several limitations to this study including the method used to measure radiation dosing which was DAP as recorded by the x-ray system. We did not measure the radiation dose at the skin level using dosimetry since DAP has been previously shown to correlate well with actual skin dose [20]. Another limitation is the lack of randomization in the independent blinded review process which likely led to the high concordance rate between SA and DARCA as the reviewers evaluated SA first followed by DARCA angiograms. Future fully blinded studies evaluating the image content alone of DARCA compared to SA are warranted and on-going. Additionally, reviewers were not asked to provide a degree of stenosis for each lesion as the focus was more on the screening adequacy of DARCA. We chose not to have the reviewers perform this as it was addressed in a recent publication [9]. Another limitation of this study is the exclusion of CABG patients. We chose not to include CABG patients as the FOV required to contain the graft would be at least 13 in. while 8 in. would be used in SA with panning. This would have made the screening adequacy of DARCA versus SA inherently bias towards SA. Future studies of DARCA should include this patient subset to address the efficacy of DARCA to visualize graft lesions and native collaterals.

Our study is comparable to the only other evaluation of DARCA. In this small study by Horisaki et al. [21], 13 patients underwent DARCA which was compared to 13 separate patients undergoing SA using a biplane system. In our cross-over study, we used single-plane SA and only required six cineangiograms while in the study by Horisaki, nine runs were required, which is likely closer to standard practice. Despite the use of more images the study also demonstrated significant reductions in contrast utilization and radiation exposure and a neutral effect on procedural time. The adequacy of the type of acquisition to evaluate for CAD was only performed by the operator and this study lacked any evaluation of image content. Our study confirms in a larger cohort these pilot study findings of the safety and efficacy of DARCA.

DARCA is a safe and effective method to perform coronary angiography and represents another step forward in the pursuit of safer imaging techniques in the evaluation of CAD. Use of DARCA as the routine technique for performing coronary angiography would substantially lower the radiation burden and contrast volume for patients. Our study documents that this acquisition technique can provide comparable image quality in a safer and more efficient manner.

ACKNOWLEDGEMENTS

The authors acknowledge Tom Maddox, M.D. and Meg Plomondon, Ph.D. for their statistical assistance.

REFERENCES

1. Arnett EN, Isner JM, Redwood DR, et al. Coronary artery narrowing in coronary heart disease: Comparison of cineangiographic and necropsy findings. *Ann Intern Med* 1979;91:350–356.
2. De Scheerder I, De Man F, Herregods MC, Wilczek K, Barrios L, Raymenants E, Desmet W, De Geest H, Piessens J. Intravascular ultrasound versus angiography for measurement of luminal diameters in normal and diseased coronary arteries. *Am Heart J* 1994;127:243–251.
3. Isner JM, Kishel J, Kent KM, Ronan JA Jr, Ross AM, Roberts WC. Accuracy of angiographic determination of left main coronary arterial narrowing. Angiographic–histologic correlative analysis in 28 patients. *Circulation* 1981;63:1056–1064.
4. Mintz GS, Painter JA, Pichard AD, Kent KM, Satler LF, Popma JJ, Chuang YC, Bucher TA, Sokolowicz LE, Leon MB. Atherosclerosis in angiographically “normal” coronary artery reference segments: An intravascular ultrasound study with clinical correlations. *J Am Coll Cardiol* 1995;25:1479–1485.
5. Mizuno K, Miyamoto A, Satomura K, Kurita A, Arai T, Sakurada M, Yanagida S, Nakamura H. Angioscopic coronary macro-morphology in patients with acute coronary disorders. *Lancet* 1991;337:809–812.
6. Nissen SE, Gurley JC, Grines CL, Booth DC, McClure R, Berk M, Fischer C, DeMaria AN. Intravascular ultrasound assessment of lumen size and wall morphology in normal subjects and patients with coronary artery disease. *Circulation* 1991;84:1087–1099.
7. Schwartz JN, Kong Y, Hackel DB, Bartel AG. Comparison of angiographic and postmortem findings in patients with coronary artery disease. *Am J Cardiol* 1975;36:174–178.
8. Akhtar M, Vakharia KT, Mishell J, Gera A, Ports TA, Yeghiazarians Y, Michaels AD. Randomized study of the safety and clinical utility of rotational vs. standard coronary angiography using a flat-panel detector. *Catheter Cardiovasc Interv* 2005;66:43–49.
9. Garcia JA, Agostoni P, Green NE, Maddux JT, Chen SY, Messenger JC, Casserly IP, Hansgen A, Wink O, Movassaghi B, Groves BM, Van Den Heuvel P, Verheye S, Van Langenhove G, Vermeersch P, Van den Branden F, Yeghiazarians Y, Michaels AD, Carroll JD. Rotational vs. standard coronary angiography: An image content analysis. *Catheter Cardiovasc Interv* 2009;73:753–761.
10. Maddux JT, Wink O, Messenger JC, Groves BM, Liao R, Strzelczyk J, Chen SY, Carroll JD. Randomized study of the safety and clinical utility of rotational angiography versus standard angiography in the diagnosis of coronary artery disease. *Catheter Cardiovasc Interv* 2004;62:167–174.
11. Baim D, Grossman W. Coronary angiography. In: Grossman’s Cardiac Catheterization, Angiography, and Intervention, 6th ed. Philadelphia, PA: Lippincott Williams & Wilkins;2000. pp 232–245.
12. Garcia JA, Movassaghi B, Casserly IP, Klein AJ, Chen SY, Messenger JC, Hansgen A, Wink O, Groves BM, Carroll JD. Determination of optimal viewing regions for X-ray coronary angiography based on a quantitative analysis of 3D reconstructed models. *Int J Cardiovasc Imaging* 2009;25:455–462.
13. Kuon E, Niederst PN, Dahm JB. Usefulness of rotational spin for coronary angiography in patients with advanced renal insufficiency. *Am J Cardiol* 2002;90:369–373.
14. Raman SV, Morford R, Neff M, Attar TT, Kukielka G, Magorien RD, Bush CA. Rotational X-ray coronary angiography. *Catheter Cardiovasc Interv* 2004;63:201–207.
15. Garcia JA, Chen SY, Messenger JC, Casserly IP, Hansgen A, Wink O, Movassaghi B, Klein AJ, Carroll JD. Initial clinical experience of selective coronary angiography using one prolonged injection and a 180 degrees rotational trajectory. *Catheter Cardiovasc Interv* 2007;70:190–196.
16. McCullough PA, Wolyn R, Rocher LL, Levin RN, O’Neill WW. Acute renal failure after coronary intervention: Incidence, risk factors, and relationship to mortality. *Am J Med* 1997;103:368–375.
17. Mehran R, Aymong ED, Nikolsky E, Lasic Z, Iakovou I, Fahy M, Mintz GS, Lansky AJ, Moses JW, Stone GW, Leon MB, Dangas G. A simple risk score for prediction of contrast-induced nephropathy after percutaneous coronary intervention: Development and initial validation. *J Am Coll Cardiol* 2004;44:1393–1399.
18. Mehran R, Nikolsky E. Contrast-induced nephropathy: Definition, epidemiology, and patients at risk. *Kidney Int Suppl* 2006 Apr (100):S11–S15.
19. Roriz R, de Gevigney G, Finet G, Nantois-Collet C, Borch KW, Amiel M, Beaune J. Comparison of iodixanol (Visipaque) and ioxaglate (Hexabrix) in coronary angiography and ventriculography: A double-blind randomized study. *J Radiol* 1999;80:727–732.
20. Chida K, Saito H, Otani H, Kohzuki M, Takahashi S, Yamada S, Shirato K, Zuguchi M. Relationship between fluoroscopic time, dose-area product, body weight, and maximum radiation skin dose in cardiac interventional procedures. *Am J Roentgenol* 2006;186:774–778.
21. Horisaki T, Katoh O, Imai S, Inada T, Suzuki T, Inuma K, Sugiura H, Bakker N, Melman N. Feasibility evaluation of dual axis rotational angiography (XperSwing) in the diagnosis of coronary artery disease. *MedicaMundi* 2008;52:11–13.