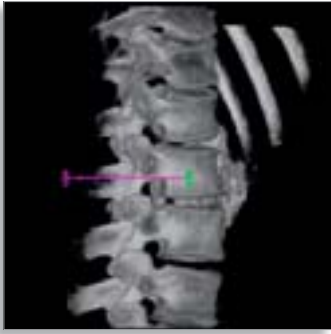



Live 3D Guidance with XperGuide

A targeted delivery of anesthetics during lumbar sympathetic ganglion block

Who/where

Dr. John Racadio, Chief of Interventional Radiology, Cincinnati Children's Hospital Medical Center, Cincinnati Ohio, USA

Challenge

Confidently deliver lidocaine anesthetic and steroidal therapy with precision and efficacious results in the X-ray angio suite.

Solution

Employ Philips XperCT for 3D spatial clarity and Philips XperGuide for image guided needle placement.

Dr. John Racadio demonstrates procedural efficiency and operational command of new tableside 3D interventional tools in an innovative non-vascular application. "It's actually really cool," laughs Dr. Racadio when discussing real-time image-based needle guidance. "With proper execution, XperGuide informs you every step of the way."

History of pioneering work

During his tenure at Cincinnati Children's Hospital Medical Center, Dr. Racadio has proven himself a leader in the development of innovative clinical procedures for infants, children and adolescents. As early as 2003 he was demonstrating how 3D-RA vastly improved spatial orientation and eliminated guesswork during the embolization of angiomyolipomas.

Today, with a new Allura Xper FD20 X-ray angio system, Dr. Racadio is pushing the envelope once again by creatively employing two new 3D interventional tools – XperCT and XperGuide.

A request to assist

"I was called in to help with a lumbar plexus block, working alongside one of our pain anesthesiologists. The patient was a teenager with a vascular malformation of the left thigh and chronic neuropathic lower leg and foot pain."

"The idea," he says, "was to inject some long lasting lidocaine and steroid along the course of the lumbar sympathetic ganglion (just in front of the vertebral bodies at the L1-L3 level), immediately adjacent to the aorta. The trick is seeing your way to the precise location."

If the delivery needle is not placed close enough to the nerve plexus, clinical relief is jeopardized.

PHILIPS



Dr. John Racadio

Traditional techniques

Advancing the needle to the proper location has most commonly been done under fluoroscopic or CT guidance, both of which have shortcomings.

Dr. Racadio explains, “With live fluoro you can do a little test injection of dye to see where the needle tip is. And you can watch it spread to make sure it is not getting swept away within some retroperitoneal or lumbar vein. The downside of live fluoro is that all you see are bones. There’s no indication of soft tissue structure. If your needle skin entry site is too far lateral (on the back), the bowel, colon, and kidney can get in the way. These are structures you shouldn’t go through.”

“XperGuide gives him accurate, real-time needle advancement guidance based on his own user-defined trajectories”

“On the other hand, with CT you benefit from seeing the organ structures and can guide your needle right down to where it needs to be. But you don’t have the live fluoro capabilities of injecting contrast to see where it’s spreading and to be sure it’s not being injected into a vascular structure.”



XperCT shows predefined needle path

New tools, new views

Now with the XperCT feature of the Philips angio suite, Dr. Racadio acquires CT-like images right in his interventional lab. Improvements in planning, guidance and evaluation are accomplished while the patient is on the table.

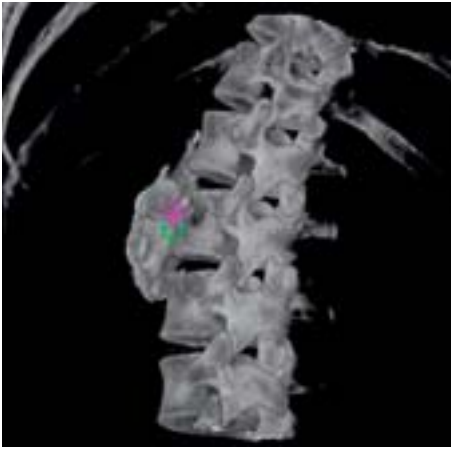
XperCT reconstructs 3D volumes from rotational fluoroscopy acquisitions. The acquired images (with or without contrast) are automatically reconstructed into an isotropic soft-tissue volume, which can be viewed and manipulated both in the control room as well as tableside, in the examination room.

Once the XperCT scan is completed, Dr. Racadio calls on XperGuide to assist him in proper needle placement. XperGuide gives him accurate, real-time needle advancement guidance based on his own user-defined trajectories. Under live fluoroscopy, superimposed on the acquired XperCT images, he can more confidently position the needle for treatment.

Setting the course

For the lumbar sympathetic ganglion block, the teenager was sedated and immobilized in a prone position on the table. An XperCT dataset was acquired and reconstructed tableside for Dr. Racadio to review. He then turned to XperGuide.

“On the workstation we picked our skin entrance site and our target destination site (just between the aorta and the anterior vertebral body in the retroperitoneal area). I hit a button, and XperGuide gave me the distance from site to site, with the two points displayed on screen as little round circles with an ‘x’ through them.”



XperGuide path planning, bull's eye view

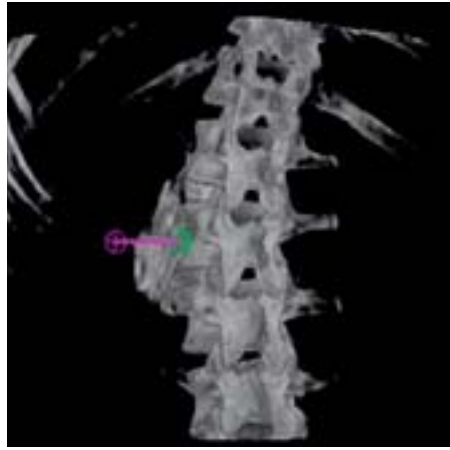
Based on this pre-defined point-to-point path, the system calculates the most optimal projections that the X-ray system geometry must take in order to provide needle advancement visualization. XperGuide then automatically rotates the c-arm to the proper needle insertion position. Now the entrance point and the target point are directly superimposed over each other, showing the proper path of the needle.

Following the pathway

Needle angling is supported by laser guidance and needle depth is assessed by way of live fluoroscopy. Any deviation from the predefined trajectory is immediately seen on the monitor and can be corrected.

“In the progression view I could see the entire length of my needle superimposed over the line graphic.”

“To begin the procedure,” says Dr. Racadio. “Under fluoroscopy I placed my needle tip on the center of the target, keeping the hub of the needle projected over the tip, straight along the path I needed to go. A table mounted laser can then be aligned along the shaft of the needle. Once I was confident of my direction, I switched to progression view.”

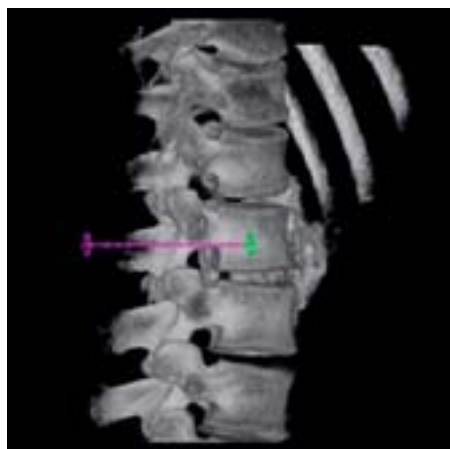

Posterior view

“I kept advancing until the tip reached the destination target at the end of that graphic. It's that easy.”

The FD20's c-arm swings immediately to an exact 90 degrees tangent to the entry position. And the image on the workstation displays a color line drawn between the two points. Dr. Racadio continues to advance his needle to the proper depth, while assuring proper needle angle with the laser guide.

“In the progression view I could see the entire length of my needle superimposed over the line graphic. I kept advancing until the tip reached the destination target at the end of that graphic. It's that easy.”



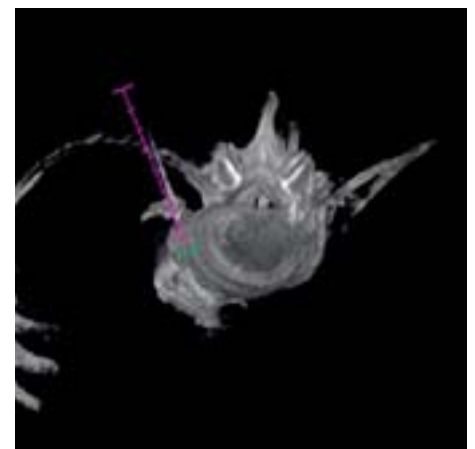
XperGuide path planing, lateral View

Confirming the position

But was XperGuide's final position really the best? “The anesthesiologist thought that based on the bony landmarks, the needle should be advanced a little further,” remembers Dr. Racadio. “After moving forward another 7mm, he removed the stylet from the needle and saw a small amount of bright red blood, indicating a prick to the aorta.”

“We pulled the needle back to the position shown on the XperGuide and injected some contrast under fluoroscopy. It showed good distribution of dye wrapping around the aorta and sitting in the exact location we wanted. It was evident there was no progression of contrast into any vascular structure, including the aorta. So with the needle tip satisfactorily positioned, we went ahead and injected the anesthetic and steroid.”

“Finally, to get a better understanding of the final distribution of anesthetic, we did a post injection XperCT. We found it to be perfectly positioned – bathing the proper area and providing the teen with maximum relief.”



Axial view

Creative application of technology

Dr. Racadio insists less invasive procedures have always been the goal in interventional radiology, with improved efficiency and better patient outcome the result. He believes advancements like XperCT and XperGuide will help clinicians rethink their approach in many situations.

“I like XperCT for the same reason I first liked 3D-RA. It gives me something that was always missing in the angio suite - in this case the ability to visualize surrounding soft tissues. Now I have the three dimensional spatial orientation I need to use a tool like XperGuide. I can easily get my needle to an exact location and avoid major organs along the way.”

“XperCT and XperGuide together allow me to paint with a finer paintbrush – to be truly minimally invasive.”



© 2008 Koninklijke Philips Electronics N.V.
All rights are reserved.

Philips Medical Systems Nederland B.V. reserves the right to make changes in specifications and/or to discontinue any product at any time without notice or obligation and will not be liable for any consequences resulting from the use of this publication.

Philips Healthcare is part of Royal Philips Electronics

www.philips.com/healthcare
healthcare@philips.com
fax: +31 40 27 64 887

Printed in The Netherlands
4522 962 19901/722 * APR 2008

Philips Healthcare
Global Information Center
P.O. Box 1286
5602 BG Eindhoven
The Netherlands