3D TEE leads to life-saving TAVR procedure

Who/where
George Gellert, MD

Ashish Pershad, MD

Cavanagh Heart Center
Banner Good Samaritan
Medical Center
Phoenix, AZ USA

Challenge
Conduct an accurate measurement of the aortic annulus to determine patient suitability for TAVR procedure

Solution
Live 3D TEE with Philips iE33 xMATRIX ultrasound system

When the elderly man arrived at interventional cardiologist Ashish Pershad, MD's office, he was so chronically short of breath that he could barely complete a word, let alone a sentence. Months earlier, he had pinned his hopes for recovery on a transcatheter aortic valve replacement (TAVR) procedure that had been scheduled at another hospital. When that procedure was aborted because 2D echo in the cath lab raised concerns that his aortic annulus was too large, he thought he was out of options.

Ashish Pershad, MD
Interventional Cardiologist
Structural Heart Program

He spent the six months following that aborted procedure in and out of the hospital, struggling with congestive heart failure and fighting for every breath. "His lung specialist referred him to another cardiologist for a second opinion, and that cardiologist referred him to me," Pershad says.

3D TEE offers new hope

Pershad immediately called in George Gellert, MD, the medical director of the Interventional Echocardiography, Structural Heart Program, at Cavanagh Heart Center, Banner Good Samaritan Medical Center. When Gellert met the patient, he knew nothing of the prior attempt at a TAVR procedure. "The cardiologists know that I don't want to hear a lot ahead of time, because I don't want it to influence me," Gellert says.

George Gellert, MD
Medical Director
Interventional Echocardiography
Structural Heart Program

After performing a Live 3D TEE (transesophageal echo) exam using a Philips iE33 xMATRIX ultrasound system, Gellert concluded that the patient's annulus size was compatible with a Sapien valve transplant, and recommended proceeding with the TAVR procedure.

PHILIPS

Remarkable recovery

Just a day after the procedure, the man who could hardly catch his breath when he met Pershad and Gellert was walking around the ICU, and today it is hard to imagine he ever considered himself near life's end.

His quick recovery is not unusual. TAVR, aided by echocardiography, has restored the lives of many patients. "It is an amazing feeling to know that before there was nothing that we could do, but now there is this therapy, and within hours, patients say, 'I can breathe,'" Gellert says.

Cardiothoracic surgeon H. Kenith Fang, MD is a member of the TAVR team.

TAVR is a promising option for patients who are deemed too high risk for surgery. Frail and very ill, patients with severe aortic stenosis who do not receive therapy return often to the hospital, decreasing their quality of life and placing a burden on the healthcare system. For this reason, Gellert says that TAVR makes both therapeutic and economic sense. "Once you invest in this valve replacement therapy, you may reduce all those hospital visits, and the patient lives a decent life," he says. "This patient population is the sickest of the sickest, and yet once we put a valve in, ninety percent of the time I can wake them up in the operating room and they can talk to us."

Good Samaritan offers valve replacement using the Edwards Sapien transcatheter heart valve, and is also part of the Medtronic Corevalve clinical trial. The site has performed 90 TAVR procedures using the Sapien valve, and approximately 100 using the Corevalve.

Procedure relies on accurate annulus measurement

Accurate measurement of the aortic annulus is crucial to the TAVR procedure. In the United States, two Sapien valve sizes are available, and patients with aortic annuli smaller than 18 mm or larger than 25 mm cannot receive the valve. Inaccurate measurements may result in unnecessary denial or inappropriate approval of therapy. In addition, improper valve sizing can lead to paravalvular regurgitation, annular rupture, or aortic insufficiency.

3D echo provides more accuracy than 2D echo

To evaluate the annulus size, Gellert uses an X7-2t xMATRIX array transducer and the iE33 ultrasound system to obtain a Live 3D TEE data set. "I need 2-3 minutes to do the exam, and then I dissect the data using the QLAB 3DQ quantification tool," he says.

Traditionally, 2D echo is used to assess the aorta and measure aortic annulus. However, this presents several problems that can lead to inaccurate measurements.

- The 2D measurement is based on the presumption that the annulus is circular, but it is actually an irregularly shaped oval.
- 2D TEE measures the coronet-shaped basal attachments of the leaflets. Because these attachments do not transect the full diameter of the left ventricular outflow tract, this approach can result in an inaccurate measurement.

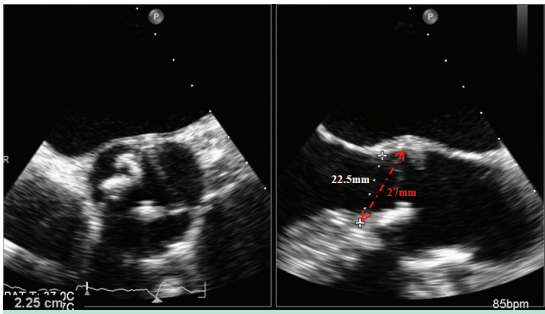

Because the aortic annulus is virtual, rather than actual, measuring the ring with 2D ultrasound is not possible. These images show how imprecise cursor placement resulted in a measurement of 27 mm, and led to the false conclusion that the patient's annulus was too large for a Sapien valve.

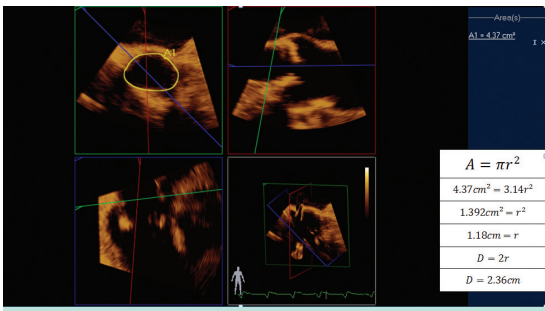

Gellert uses 3D ultrasound and Philips QLAB to precisely measure the aortic annulus. By using multi-planar reconstruction planes (red, green and blue MPRs), he can reconstruct an ellipse (shown in yellow) that marks the annulus, and then measure it accurately. Although the annulus is an ellipse, it conforms to the circular shape of the artificial valve once the valve is placed.

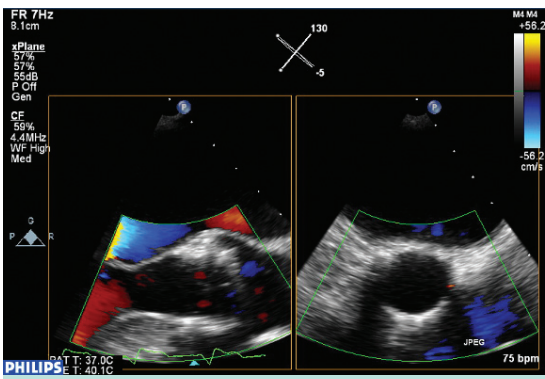

After the TAVR procedure, Gellert checks the results. The image on the right shows the new valve in place, without any paravalvular leak.

- In a heavily calcified annulus, it is difficult to determine the hinge points where two leaflets attach to the wall of the aortic root, leading to difficulty in accurately placing the cursor for measurement.

CT is first step

CT can also be used to measure the annulus, and at Good Samaritan it is the first step to assess the annulus and peripheral arteries, along with a screening echo. "If there's a question based on CT or transthoracic screening echo, then we do 3D TEE beforehand so that we have a plan in place before the procedure. If there is no question based on the CT scan and the screening echo, then we just schedule the patient for the procedure and do the 3D TEE intraoperatively," Pershad says.

Intraoperative 3D echo changes valve choice in 8-10% of patients

He adds that sometimes the intraoperative 3D TEE changes the plan. "Many times we have been fooled by a CT scan or screening echo measurement, such that we ended up choosing a different valve size when we obtain the 3D measurement," he says. "I'd estimate that in 8-10 percent of the patients, the 3D TEE indicates that the initial choice of valve would not have been the right size."

Echo-intensive procedure

The TAVR procedure uses echocardiography throughout: preoperatively to assess and measure, during valve deployment to check positioning and response, and postoperatively to check for perivalvular leaks and to assess the valve.

After the initial annulus measurement using Live 3D, Gellert uses Philips Live xPlane for the rest of the procedure. Live xPlane enables acquisition of two planes simultaneously from the same heartbeat, allowing the capture and display of twice as much information in the same time.

"I do a full echo exam at the start of the procedure, concentrating on the aortic root, and including the 3D assessment of the aortic annulus. When that is done, the next step is a balloon aortic valvuloplasty (BAV) to make more room for the new valve," Dr. Gellert explains. "Next, it is crucial to use echo to assess the aortic valve for aortic insufficiency, after which we check to see if the blood pressure is recovering from the rapid pacing that we induced to conduct the balloon valvuloplasty."

Once the delivery sheath with the valve is placed, both echo and fluoroscopy are used to determine if the valve is in the correct position for deployment. Then the heart is again set to a rapid pace to stop blood flow, and the new valve is placed. Echo is now used to determine if there are any perivalvular or intra-device leaks, if the leaflets on the valve are competent, and to assess coronary blood flow. Finally, Gellert moves the probe to the stomach to ensure that valve deployment didn't result in occlusion of coronary arteries.

Use of 3D echo increasing

Gellert was one of the first physicians in the Phoenix area to explore the utility of 3D echo, and he continues to find new ways to use it in both the cath lab and the surgical suite. What started several years ago, when he was asked to provide 3D echo for a mitral valve balloon valvuloplasty in which fluoroscopy was ineffective, has blossomed into a situation where 3D echo is used for many procedures, including atrial septal defect (ASD) repairs, as well as left atrial appendage (LAA) closures, TAVR and MitraClip.

Surgeons also benefit from 3D TEE

"Hybrid procedures (like TAVR), are truly a combined effort between cardiology, cardiac surgery, and echocardiography. Because the surgeons see the power of 3D in the TAVR procedure, they are requesting more 3D echo," Gellert says. "They don't need 3D echo to measure aortic roots, because they do that physically on the open heart.

But when it comes to mitral valve procedures, 3D echo can provide information to assess what segments or scallops of the mitral valve are diseased or to pinpoint any leaks."

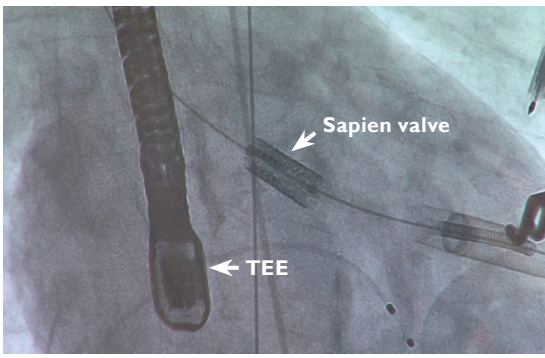

Positioning the Edwards Sapien valve with echocardiography and fluoroscopy.

iE33 image quality impresses

While Gellert has been using 3D echo for some time, his first experience with a Philips system was at Good Samaritan. He found the interface easy to learn. "The iE33 system can do a lot, so you need to invest time, but overall it is a very logical layout of the controls with a good flow to it."

"When I started to play with the iE33 system, I thought that the image quality was shockingly different, shockingly good," he adds. "I thought it my subjective assessment that even the 2D imaging was better, but then later I learned that the image quality is the result of Philips PureWave xMATRIX technology.

Philips Healthcare is part of Royal Philips Electronics

How to reach us
www.philips.com/healthcare
healthcare@philips.com

Asia
+49 7031 463 2254

Europe, Middle East, Africa
+49 7031 463 2254

Latin America
+55 11 2125 0744

North America
+1 425 487 7000
800 285 5585 (toll free, US only)

Please visit www.philips.com/iE33

© 2013 Koninklijke Philips Electronics N.V.
All rights are reserved.

Philips Healthcare reserves the right to make changes in specifications and/or to discontinue any product at any time without notice or obligation and will not be liable for any consequences resulting from the use of this publication.

Philips Healthcare is part of Royal Philips Electronics

www.philips.com/healthcare
healthcare@philips.com

Printed in The Netherlands
4522 962 92461 * MAR 2013