



Clinical effectiveness of PureWave technology in imaging obese patients

Results of a six-site study

The World Health Organization reports that more than one in ten of the world's adult population is obese.¹ Obese patients present special challenges for ultrasound imaging, because it is difficult to achieve the penetration required for high quality, diagnostic images. As a result, pathology may be missed, or patients may require additional imaging studies that can increase the cost of diagnosis and expose patients to unnecessary radiation. In addition, the inability to obtain diagnostic images disrupts imaging providers' workflow and may lead to lost revenue. Obese patients impact sonographers as well, who must push harder to get quality images, increasing strain that may lead to injuries, which may result in long exams.

Philips C5-1 PureWave transducer is designed to make imaging obese patients easier. It employs Philips-exclusive PureWave technology, for acoustic efficiency in transducer tuning and system optimization that facilitates imaging of a wide range of patient types with fewer artifacts and better penetration.

In addition, its tissue aberration correction technology "senses" above-average amounts of adipose tissue and adjusts accordingly.

Six clinical sites tested the C5-1 PureWave transducer with tissue aberration correction and coded beamforming technologies and recorded their observations. Each site was asked to complete 50 to 75 technically difficult patient ultrasound exams using the C5-1 PureWave transducer on the iU22 ultrasound system, and compare results based on previous experience with conventional technologies. They then completed a questionnaire about their experiences.

Clinical sites conducting the study

The clinical sites participating in the study were:

- University of Alabama Hospital and the Kirklin Clinic; Birmingham, Alabama, USA
- University of Texas M.D. Anderson Cancer Center; Houston, Texas, USA
- Cliniques Universitaires Saint Luc UCL; Brussels, Belgium
- University of Colorado; Denver, Colorado, USA
- St. Paul's Hospital; Vancouver, British Columbia, Canada
- Freeman Hospital; Newcastle Upon Tyne, UK

Summary of results

Below are the combined summary results from the participating sites. Individual results from each site can be found in the following pages.

- Exam times reduced by 2% to 38%
- A reduction in pain and fatigue from scanning in 29% to 85% of the cases
- Sonographers felt that they had to push less in 48% to 93% of the cases in order to achieve penetration of an organ or structure
- Marked improvement in color sensitivity in 31% to 86% of the cases
- Using the C5-1 transducer prevented a recommendation for additional studies with CT and/or MR due to an inadequate ultrasound study in 8% to 69% of the cases

¹ <http://www.who.int/mediacentre/factsheets/fs311/en/index.html>

Sophisticated technologies for difficult exams

The C5-1 PureWave transducer employs sophisticated technology to support excellent image quality and reduced operator strain, even when imaging obese patients.

C5-1 transducer design

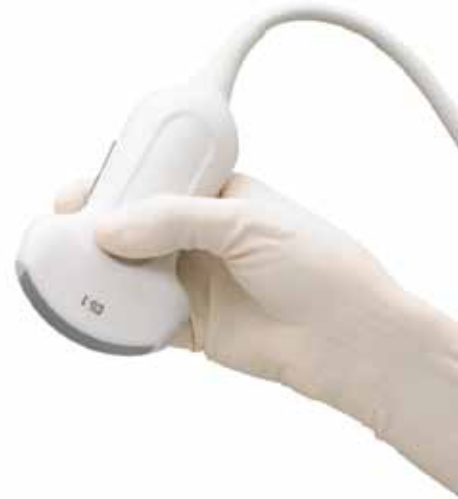
Extraordinary design efforts have resulted in a powerful transducer that is both lightweight and easy to hold, for reduced fatigue during scanning. The C5-1 features a highly flexible cable and optimal transducer balance that contributes to scanning comfort during extended or difficult exams. In addition, minimized elevation dimension improves intercostal access when imaging challenging patients with reduced rib spaces.

PureWave crystal technology

The C5-1 uses Philips-exclusive PureWave crystal technology. PureWave crystals are the result of a manufacturing technique that creates a near-perfect atomic level arrangement. The uniformity and lack of grain boundaries help transfer energy with up to 85% greater precision and efficiency over conventional materials. Their extended bandwidth covers the frequency range of two transducers, with improved Doppler performance and highly sensitive harmonic imaging.

Tissue aberration correction technology

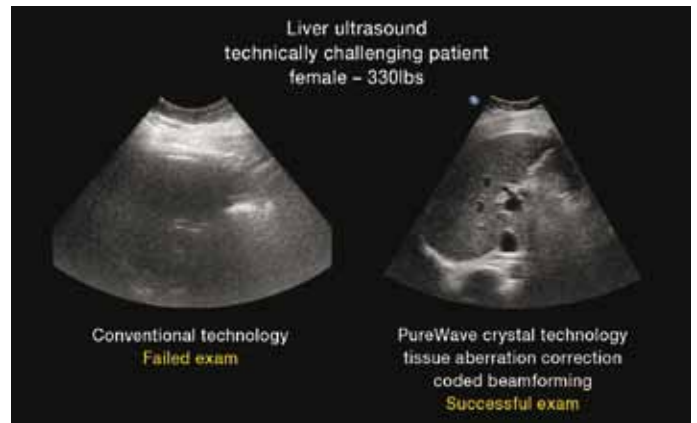
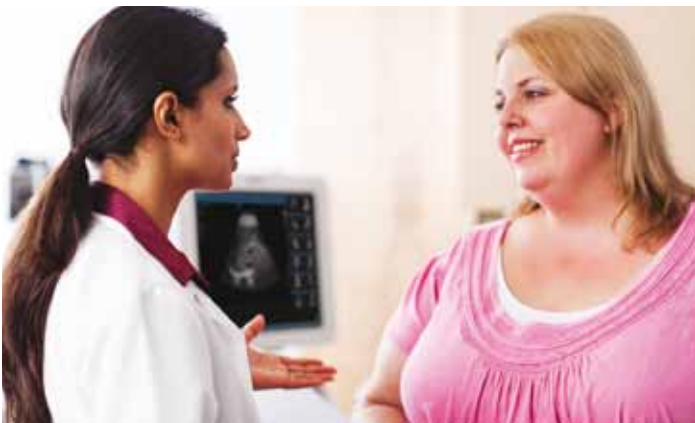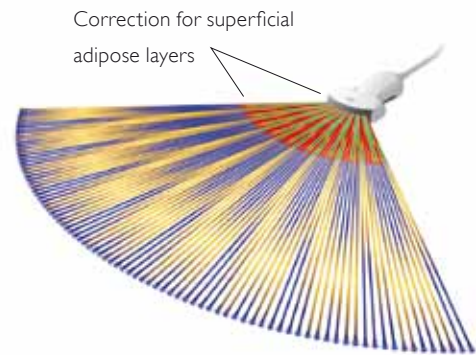
A main cause of ultrasound image degradation arises from the improper assumption of speed of sound characteristics when scanning patients with significant adipose layers. The resulting beam aberrations account for the loss of detail resolution seen on obese patients. The C5-1 PureWave transducer works in conjunction with the iU22 xMATRIX, CX50, and HD15 ultrasound systems to accommodate for the altered speed of high-frequency sound waves through adipose layers versus other tissue. In this unique mode, the ultrasound system becomes “aware” of increased adipose content and applies aberration correction algorithms. The result is increased sharpness and clarity in image quality throughout the entire beam length.



Conventional PZT material (800x)



PureWave crystal material (800x)



University of Alabama Hospital and the Kirklin Clinic

Birmingham, Alabama

Michelle L. Robbin, MD

Franklin Tessler, MD

Describe the technically difficult patients that you encounter in your lab.

We have a large proportion of obese patients whose livers and other abdominal organs are more than four to five centimeters deep, representing a significant diagnostic challenge. Additionally, we have large numbers of people with hepatic steatosis, diagnosed as an echogenic liver of varying severity. A significant proportion of our patient's livers are so fatty that we can only say they have a liver, but cannot characterize it further.

What happens when you encounter a technically difficult patient?

It definitely takes longer to perform an ultrasound on a technically difficult patient. Image optimization is more difficult, and the sonographer has to work harder to create acceptable images. The sonographer may have to try several different transducers before settling on the transducer that provides adequate penetration yet yields diagnostic images. We perform a large number of challenging abdominal Doppler studies on cirrhotic patients, patients with suspected renal artery stenosis, and immediately postoperative liver transplant patients. Acquiring images and Doppler waveforms quickly has been a challenge before the iU22, especially in the small cirrhotic liver. The patient has to be sent to CT or MR when we are unable to confidently exclude liver lesions, which is often impossible in a cirrhotic patient, or one with severe steatosis.

Summarize the results of your technically difficult patient study using the C5-1.

At least one of my sonographers typically has finger and hand numbness during a long renal artery Doppler study. When she used the C5-1 transducer, she did not have finger and hand numbness because of the superior transducer ergonomics. In another study, we were able to get diagnostic images of the renal artery stenosis we suspected was present but were unable to demonstrate without the abdominal penetration mode.

- Exam time reduced 19%
- A reduction in pain and fatigue from scanning in 77% of the cases
- Sonographers felt that they had to push less in 77% of the cases in order to achieve penetration of an organ or structure
- Marked improvement in color sensitivity in 79% of the cases
- The C5-1 prevented a recommendation for CT or MR, due to inadequate ultrasound study, in 43% of cases.

“We sonologists loved the images – ‘What a great image’ was a frequent comment.”

“Good penetration of fatty liver.”

“We clearly showed innumerable liver lesions in a patient in whom an ultrasound previously from another vendor only showed a heterogenous liver. Similarly, we showed many more liver lesions in another patient with the (C5-1) on the iU22.”

University of Texas M.D. Anderson Cancer Center

Houston, Texas

Deepak Bedi, MD

Describe the technically difficult patients that you encounter in your lab.

Large patients, fatty liver, liver/renal/abdominal pathology, large fibroids, gassy patients, ICU patients.

What happens when you encounter a technically difficult patient?

It takes more time to do the ultrasound exam. There is greater strain on the sonographer. It takes more of the radiologist's time.

Summarize the results of your technically difficult patient study using the C5-1.

Found it easier to see deep organs on large patients. Did not have to "reach" and strain to find an acoustic window.

- Exam time reduced by 16%
- A reduction in pain and fatigue from scanning in 30% of the cases
- Sonographers felt that they had to push less in 48% of the cases in order to achieve penetration of an organ or structure
- Marked improvement in color sensitivity in 61% of the cases
- The C5-1 prevented a recommendation for CT or MR, due to inadequate ultrasound study, in 9% of cases.

"Useful for critically ill patients, with multiple lines, tubes, etc., where the C5-1 allows you penetration without looking for the ideal acoustic window."

"Particularly suitable for imaging deep-seated kidneys and liver, without sweating over the anterior approach."

"Sonographers did not have to rearrange equipment, reposition themselves or dig hard to get images."

Cliniques Universitaires Saint Luc UCL

Brussels, Belgium

Etienne Danse, MD, PhD

Mohamed Kichouh, Sonographer

Describe the technically difficult patients that you encounter in your lab.

Obesity and fatty liver, modification of the liver texture related to chemotherapy, large amounts of bowel gas, non-cooperative patients, post-operative evaluation (in critical care units) with a large amount of color Doppler studies of the liver and the kidneys, large amount of color Doppler studies of the kidneys in patients with hypertension, diabetes mellitus, and renal function impairment.

What happens when you encounter a technically difficult patient?

Increased time for the examination (sometimes with a doubling time), increased pressure on the skin; in some of these cases the ultrasound results are not enough for giving an optimal answer and the patients are referred to MR or CT.

Summarize the results of your technically difficult patient study using the C5-1.

- Exam time reduced by 38%
- A reduction in pain and fatigue from scanning in 85% of the cases
- Sonographers felt that they had to push less in 86% of the cases in order to achieve penetration of an organ or structure
- Marked improvement in color sensitivity in 86% of the cases
- The C5-1 prevented a recommendation for CT or MR, due to inadequate ultrasound study, in 69% of the cases.

“The increased performance of color mode reduces the time to insonate the majority of the patients, particularly in cases of color Doppler of the kidneys.”

“The C5-1 is more ergonomic and pleasant to use resulting in a reduction of fatigue at the end of the day.”

“The sites of treated lesions were clearly better delineated with the C5-1.”

University of Colorado Hospital

Denver, Colorado

Julia A. Drose, BA, RDMS, RDCS, RVT

Describe the technically difficult patients that you encounter in your lab.

Obesity, large amount of subcutaneous fat (not necessarily an obese person), cirrhotic livers, fatty livers, massive ascites, abdominal scars, thin-kyphotic patients, twin pregnancy, pregnant with polyhydramnios.

What happens when you encounter a technically difficult patient?

Technically difficult patients often take longer to examine and their exams are usually less diagnostic. An additional test, such as a CT, is often recommended secondary to the diagnostic limitations of the ultrasound exam. Sonographers do have to push harder or scan in awkward positions in some cases. This causes pain at the time of the exam and probably contributes to long-term injury or disability. The most important consequence of imaging a technically difficult patient is that we often cannot provide a diagnostic answer to the clinical question.

Summarize the results of your technically difficult patient study using the C5-1.

The C5-1 PureWave transducer was considered an asset to all of our sonographers. It did improve imaging in difficult patients. In 47 out of 63 cases (75%), the sonographers felt the C5-1 improved their diagnostic confidence in the exam.

- Exam time reduced 2% to 3%
- A reduction in pain and fatigue from scanning in 29% of the cases
- Sonographers felt that they had to push less in 52% of the cases in order to achieve penetration of an organ or structure
- Marked improvement in color sensitivity in 78% of the cases
- The C5-1 prevented a recommendation for CT or MR, due to inadequate ultrasound study, in 8% of cases.

“Great improved penetration – visualization of structures.”

“Improved penetration of fatty liver.”

“Didn’t press hard, patient in pain – still got good image.”

St. Paul's Hospital

Vancouver, British Columbia

Cathy Fix, RDMS, Ultrasound Supervisor

Describe the technically difficult patients that you encounter in your lab.

Obese patients, fatty and cirrhotic livers, technically challenging patients with poor acoustic windows.

What happens when you encounter a technically difficult patient?

This has a significant impact to our lab in having to spend more time on each patient, making fewer exams possible, and decreasing diagnostic confidence. This increase in difficulty also places more physical strain on our sonographers, which can lead to injury as well as creating the need for further diagnostic imaging tests when the ultrasound examination does not give optimal results.

Summarize the results of your technically difficult patient study using the C5-1.

We increased our diagnostic confidence for all of our obstetrical exams. We also increased confidence in liver exams including technically difficult patients and those with fatty infiltration or cirrhosis.

- Exam time reduced 4%
- A reduction in pain and fatigue from scanning in 54% of the cases
- Sonographers felt that they had to push less in 64% of the cases in order to achieve penetration of an organ or structure
- Marked improvement in color sensitivity in 31% of the cases
- The C5-1 prevented a recommendation for CT or MR, due to a suboptimal ultrasound examination, in 29% of cases.

“Didn't have to work so hard to get diagnostic images.”

“Increase in diagnostic confidence especially with fetal heads and fetal hearts.”

“We need penetration and good spatial and contrast resolution and the C5-1 has those.”

“Lack of artifacts helping increase our diagnostic confidence.”

Freeman Hospital

Newcastle Upon Tyne, UK

Dr. Simon T. Elliott and team

Describe the technically difficult patients that you encounter in your lab.

Mostly obese patients and fatty livers; a lot of requests for retroperitoneal pathology and Doppler studies.

What happens when you encounter a technically difficult patient?

In difficult patients, the main problem is reduced diagnostic confidence, due to limited access or sensitivity.

Summarize the results of your technically difficult patient study using the C5-1.

The C5-1 definitely improves diagnostic confidence through better penetration and color Doppler sensitivity. It also increases the speed of the exam and helps in uncooperative patients.

- Exam time reduced by 34%
- A reduction in pain and fatigue from scanning in 87% of the cases
- Sonographers felt that they had to push less in 93% of the cases in order to achieve penetration of an organ structure
- Marked improvement in color Doppler in 71% of the cases
- Without the C5-1, 19% of the cases would have been referred to MR or CT

“Good penetration of fatty liver.”

“Excellent in difficult, scarred abdomen.”

“Increases speed and confidence for gallbladder and bile ducts.”

Please visit www.philips.com/purewave



© 2012 Koninklijke Philips Electronics N.V.
All rights are reserved.

Philips Healthcare reserves the right to make changes in specifications and/or to discontinue any product at any time without notice or obligation and will not be liable for any consequences resulting from the use of this publication.

Philips Healthcare is part of Royal Philips Electronics

www.philips.com/healthcare
healthcare@philips.com

Printed in The Netherlands
4522 962 89261 * OCT 2012