

A solution for structural heart disease interventions

EPIQ 7C Live 3D and EchoNavigator integration

Analysis and case studies provided by Drs. Jose Luis Zamorano, Covadonga Fernández-Golfín, and Ariana González-Gómez
University Hospital Ramón y Cajal, Madrid, Spain

Structural heart disease interventions represent a new branch of percutaneous treatments covering a wide range of diseases that were previously treated surgically or simply not addressed.

Challenge

In structural heart disease interventions fluoroscopy alone provides clear visualization of catheters and devices but leads to poor visualization of the anatomical structure. Continuous soft tissue imaging is required, which has made echocardiography an essential tool for these procedures. Two-dimensional (2D) transesophageal echocardiography (TEE) is limited in its ability to detect the position of a device or catheter relative to its surrounding structures because it requires having to mentally reconstruct the anatomical setting. Currently 3D echocardiography complements 2D imaging in many centers; however image quality is sometimes limited. Ideally, optimized image guidance for structural heart disease interventions could merge high-quality 3D presentation of cardiac anatomical information with device and catheter visualization on fluoroscopy, both in real time.

Solution

The Philips EPIQ ultrasound system provides high-quality 3D images, allowing real-time visualization of cardiac morphology as well as catheters and devices within the surrounding environment. Live 3D Echo 3DE multiplanar reconstruction (MPR) software provides tools for 3DE volume segmentation along the three axes (x, y, z) in real time or during post-processing, and also for quantitative analysis. The Philips EchoNavigator is the first multimodality system that can synchronize echocardiography and fluoroscopy in real time by tracking the movement of the TEE probe on fluoroscopy. This allows for presentation of an X-ray view and up to three echocardiography views simultaneously and in real time: an echocardiography image in the same orientation as the C-arm gantry, the standard TEE echocardiography view as on the echocardiographer's screen, and a free image that can be rotated or cropped. The system also allows placing markers in real time on a selected structure in an echocardiography image, and these markers are automatically transposed to other views, including fluoroscopy.

Impact

High-quality Live 3D images provide a better understanding of anatomy and its surroundings, leading to better understanding and guidance of the intervention. Moreover, the use of the EchoNavigator system synchronizes echocardiography and fluoroscopy images, avoiding confusion of the different perspectives of two imaging modalities. For transaortic valve implant (TAVI) procedures using Live 3D will help achieve a better understanding of the anatomy of the aortic root and its surrounding structures. With the EchoNavigator we can mark the level of the annulus, facilitating catheter guidance and prosthesis placement, which can be especially useful in less calcified valves. In our opinion, these tools can help decrease fluoroscopy time and help maximize safety for the patient and the interventionalist.

The Philips logo is displayed in a bold, blue, sans-serif font at the bottom right of the page.

Case study

We present the case of an 85-year-old man with a past medical history of hypertension, chronic kidney disease, and severe pulmonary obstructive disease. He presented with progressive shortness of breath that significantly limited his activity. He also experienced chest pain on exertion. An echocardiogram using 3D EPIQ was performed and showed severe calcific aortic stenosis, with a planimetered aortic valve area of 0.7 cm² (Figure 1) and normal LV function.

Because of the diagnosis of severe symptomatic aortic stenosis and due to high co-morbidities, TAVI was considered for this patient. Aortic annulus diameters and area were calculated using MPR software EPIQ tools (Figure 2) and based on these diameters the size of the prosthesis was chosen.

The EchoNavigator system was used during the implant. The aortic annulus was marked on 3D EPIQ images and these markers were automatically set on the X-ray image to aid guidance during the implant (Figure 3).

The procedure was performed at low radiation dose and with excellent results with no residual aortic regurgitation.

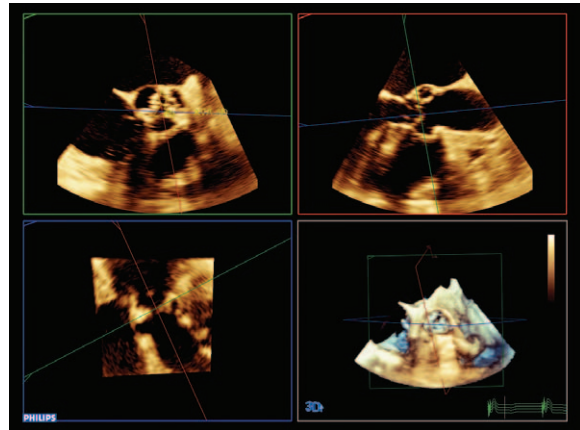


Figure 1

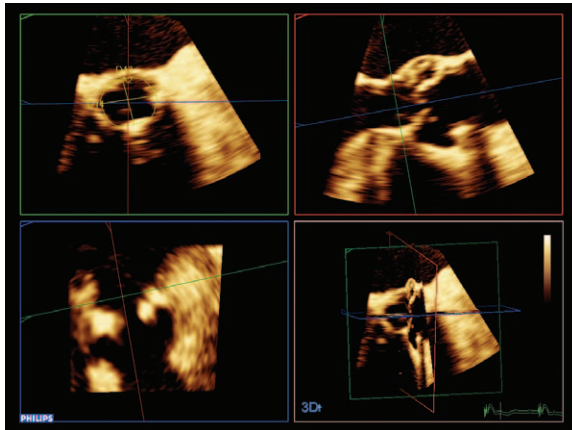


Figure 2

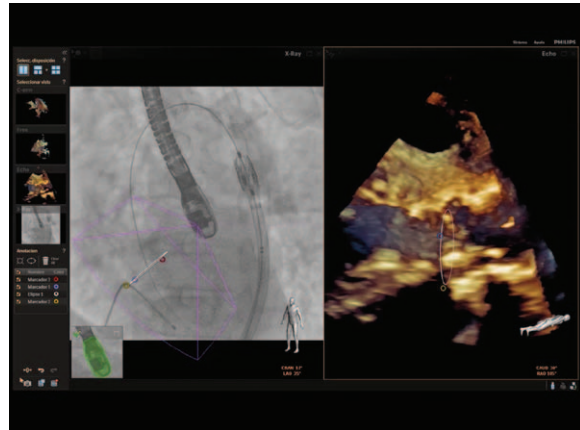


Figure 3

Please visit www.philips.com/epiq



© 2014 Koninklijke Philips N.V.
All rights are reserved.

Philips Healthcare reserves the right to make changes in specifications and/or to discontinue any product at any time without notice or obligation and will not be liable for any consequences resulting from the use of this publication.

Philips Healthcare is part of Royal Philips

www.philips.com/healthcare
healthcare@philips.com

Printed in The Netherlands
4522 991 02451 * APR 2014