

FieldStrength

Publication for the
Philips MRI Community

ISSUE 43 – MAY 2011

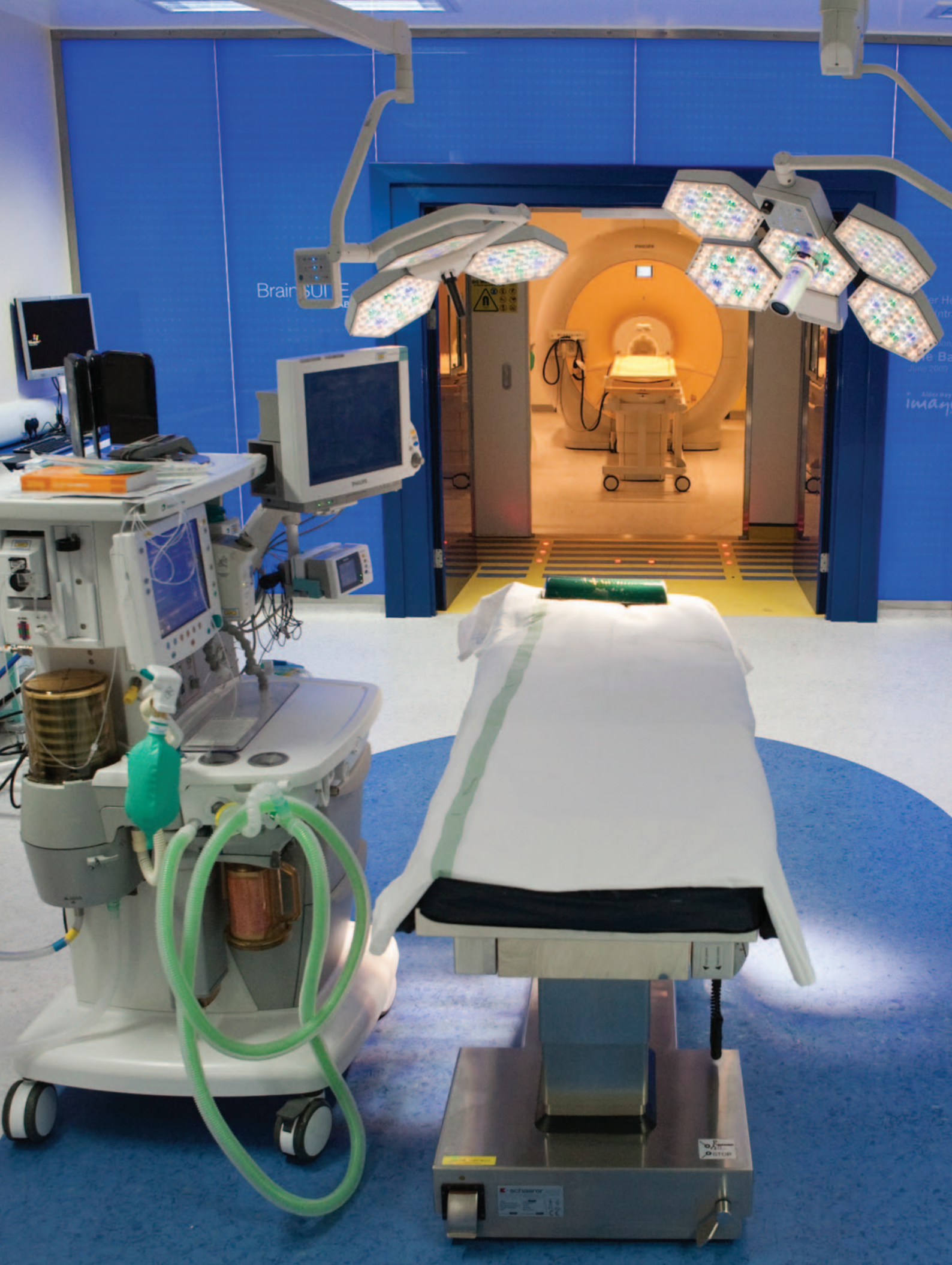MR-OR setup fulfills aims in pediatric brain surgery

Intraoperative Achieva 3.0T MR-OR helps to increase pediatric neurosurgical referrals to Liverpool children's hospital in first year.



This article is part of FieldStrength issue 43

May 2011



Brain SUR

er He
Intro
re Ba
June 2009
Alter Way
Image

**Dr. Conor Mallucci**

MB, BS, FRCS (Surgical Neurology) is a Consultant Pediatric Neurosurgeon in the Department of Pediatric Neurosurgery at Alder Hey Children's Hospital in Liverpool. He has just stepped down from chairing the British Pediatric Neurosurgery Group. He is deputy editor of the British Journal of Neurosurgery and associate editor of Child's Nervous System.

Dr. Shivaram Avula

Consultant Pediatric Radiologist, Alder Hey Children's Hospital NHS foundation Trust

“In a significant fraction of our tumor resection procedures, surgery was extended after the intraoperative MR exam.”

MR-OR setup fulfills aims in pediatric brain surgery

Intraoperative Achieva 3.0T MR-OR helps to increase pediatric neurosurgical referrals to Liverpool children's hospital in first year.

Since December 2009, [Alder Hey Children's Hospital](#), Liverpool, UK, has used an Achieva 3.0T MR-OR (dual-room setup of Achieva 3.0T suite and operating room) for intraoperative MRI (ioMR), mainly in brain tumor resection procedures. Dr. Mallucci estimates that the majority of the neuro work is pediatric brain tumors in the posterior fossa and supratentorial. The remaining work is resections for epilepsy. Because the MR system is in a separate room it can also be used for general diagnostic scanning.

CONTINUE ▶

“One reason for using MR-OR is because images used for surgical navigation lose accuracy during surgery due to brain shift and tissue removal, so an updated navigation volume scan is needed,” says Conor Mallucci, consultant neurosurgeon at the Alder Hey Children’s Hospital. “Secondly, to help you see if your surgical goal is achieved. Being able to see during surgery that resection is incomplete lessens the likelihood that a patient will need repeat surgery. Of the set of pediatric tumors we have data on, ioMR led to a significant fraction having extended surgery after their ioMR.”

Combining MR-OR with normal OR conditions

“Most people’s idea of MR-OR is of a large magnet that changes day-to-day working and prevents use of your normal equipment,” says Dr. Mallucci. “However, we have a dual-room setup with a MRI suite separated by doors from a normal operating room (OR) with plasma screen and navigation software. We use

an MRI compatible head coil with frame and an operating tabletop that slides smoothly to a trolley to transport the patient to the MRI scanner. In addition, we have the possibility to view images and control the Achieva 3.0T from within the MRI room.”

Before surgery, the patient is already pre-set up with the MR coil. Disconnecting and moving the patient on the trolley through double doors into the adjacent MRI room can be done very fast. The patient is connected to an MR compatible anesthetic trolley. After scanning, the patient returns to the OR where – if necessary – the operation can continue with updated navigation scans.

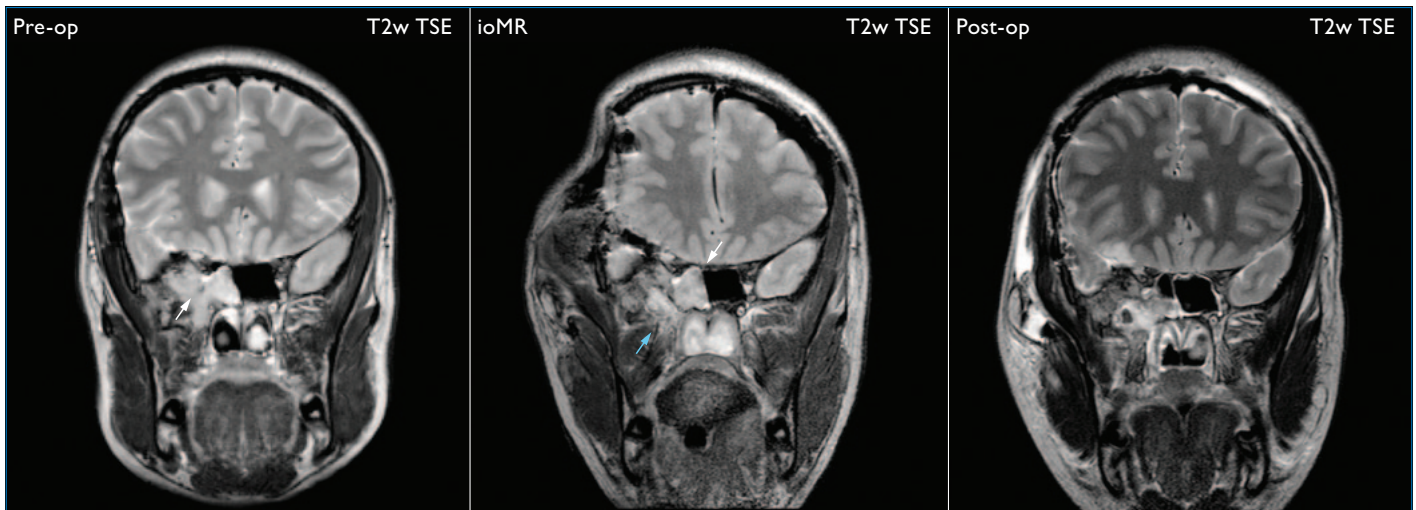
“We now use a dedicated Noras coil with head holder where fiducial markers can help make the neuronavigation much more accurate,” explains Shivaram Avula, Consultant Pediatric Radiologist at Alder Hey. “During surgery one part of the coil is placed under the head and

serves as the head holder. For intraoperative MR scanning, the top part is placed over the head. This coil offers better spatial resolution for targeting very small areas than the Flex-L coil that we initially used.”

Diagnostic and intraoperative scanning

Children under six need sedation for an MRI exam as they will not lie still. At a basic level, with an intraoperative scan, everything is done at one time. With specific preoperative sequences, an intraoperative scan and a postoperative scan all under the same anesthetic, it is one stop, one treatment, one service. The final intraoperative scan can usually serve as postoperative scan, so no further post-op exam is needed.

The preoperative study takes sometimes up to an hour, and can be done the day before the operation. It is done using the SENSE Head coil and includes a 3D T1 FFE sequence, T2 TSE in three planes and a coronal FLAIR



MR-OR of meningioma

18-year-old girl with recurrence of known extra-cranial meningioma. Pre-operative coronal T2w images reveal the infratemporal tumor (white arrow). ioMR shows residual tumor (white arrow) within the sphenoid sinus which was subsequently excised. Note that the surgical cottonoid within the resection cavity (blue arrow) can mimic residual tumor. MR-OR helped to prevent the need for a second operation. Philips Achieva 3.0T R3.2 with 8-channel SENSE Head coil used for pre-operative imaging, SENSE Flex-L coil used for intraoperative imaging.

“With specific pre-op sequences, intra-op and post-op scans all under the same anesthetic, it is one stop, one treatment, one service.”

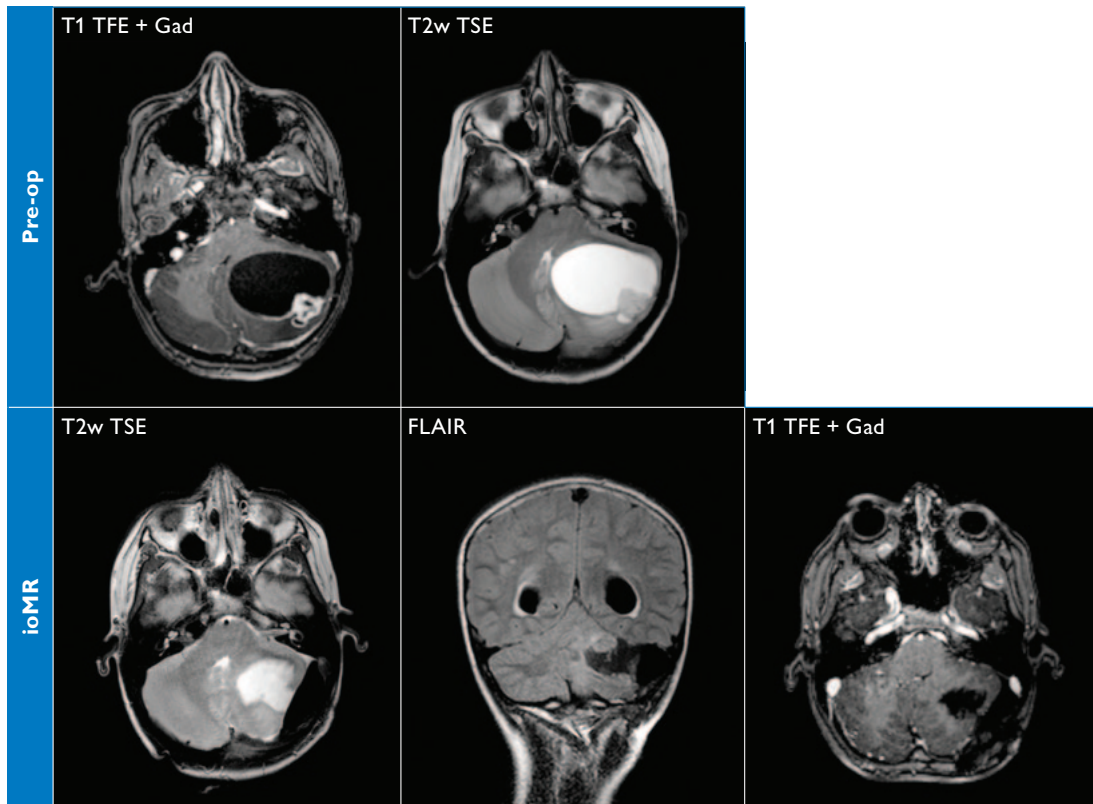
for intraoperative comparison. A dynamic susceptibility contrast (DSC) sequence is performed during contrast administration whenever possible.

An intraoperative scan to check neuro navigation is normally only a 3D T1-weighted scan to update the navigation data set. For a check on surgical goal, there is a pre-contrast

sequence, a 3D T1W and the T2W in three planes. If it appears on the non-enhanced sequences that the entire tumor or the intended extent of tumor has been removed, the gadolinium contrast is administered and post-contrast imaging is done. These scans, together with coronal FLAIR and a Diffusion Tensor Imaging (DTI), also serve as the immediate postoperative exam.

MR scanner remains available for broader use

“Our setup provides us two rooms with independent function for most of the time, during which the MR scanner functions as an outpatient scanner, independent of OR theatre activity. The ITU (Intensive Therapy Unit) is close by so it is also convenient for in-patient examinations of these children,” says Dr. Avula.



MR-OR of pilocytic astrocytoma

A 10-year-old girl presented with a history of head ache for six weeks with evidence of papilloedema and cerebellar signs on clinical examination. A posterior fossa cystic tumor with an enhancing mural nodule is seen on the axial T2W TSE and contrast-enhanced T1 TFE images. ioMR reveals complete excision of the tumor on post-contrast T1 TFE, T2W TSE and FLAIR. In our experience, the FLAIR sequence is useful in ioMR evaluation of cystic tumors, as demonstrated here. With evidence of complete tumor resection, the IOMR study serves as the early postoperative MRI, which was traditionally performed 24-48 hours post tumor resection. A repeat early MRI scan (which in some cases requires general anesthesia) was not required.

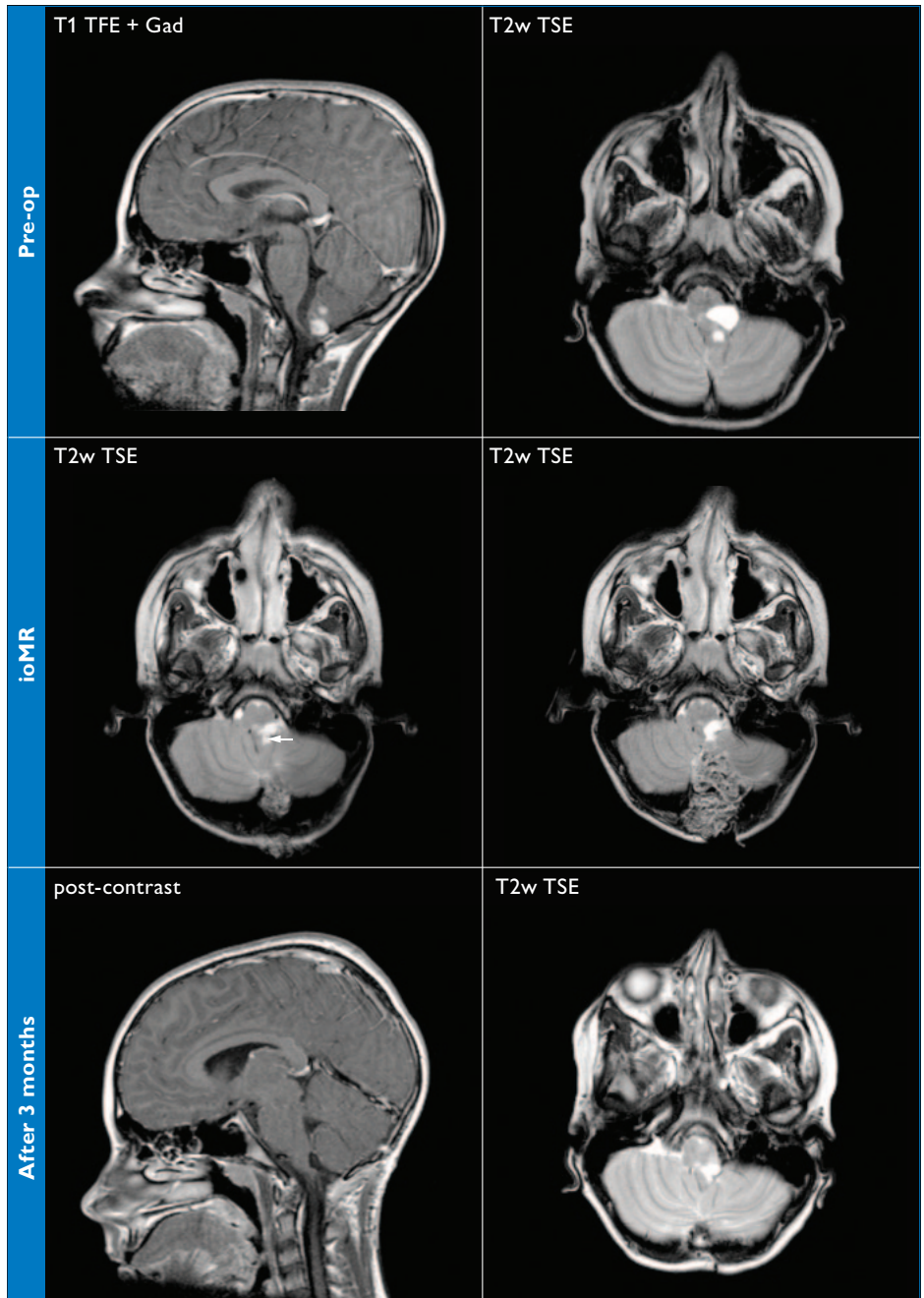
Philips Achieva 3.0T R3.2 with 8-channel SENSE Head coil used for pre-operative imaging, SENSE Flex-L coil used for intraoperative imaging. T1 TFE with 1 mm isotropic voxels, T2 FLAIR with 1 mm in-plane resolution, T2W TSE with 0.6 x 0.7 mm resolution.

CONTINUE

Apart from its intraoperative use, our Achieva 3.0T exams were general diagnostics in brain, musculoskeletal and some spine”, he continues. “Compared with our Achieva 1.5T, the 3.0T field strength offers higher resolution neuro imaging, especially in epilepsy and other complex neurology. We can now provide a much better MRI service than before.”

MR-OR, final thoughts

Having the MRI suite and the OR theatre independently available is ideal for cost effectiveness, according to Dr Mallucci. “From a patient efficiency perspective, we see MR-OR adds a time penalty of 1 to 1.5 hours. However, the clear benefit is that in cases where the MR-OR setup helps to visualize an incomplete resection, we can immediately address the issue using updated navigation data and thus avoid a second surgery. In addition the final ioMR replaces the postoperative MRI that we used to perform,” summarizes Dr. Mallucci. ■



References

Hayhurst C, Byrne P, Eldridge P R, Mallucci C L
Application of electromagnetic technology to neuro-navigation: a revolution in image-guided neurosurgery
 J Neurosurg 2009 Dec; 111(6) 1179-84

Hayhurst C, Beems T, Jenkinson M D, Byrne P, Clark S, Kandasamy J, Goodden J, Tewarie R D, Mallucci C L
Effect of Electromagnetic-navigated Shunt Placement on failure rates: A Prospective Multicentre Study
 J Neurosurg. 2010 Dec; 113(6) 1273-8, Epub 2010 Apr 16

MR-OR of pilocytic astrocytoma

A 15-year-old-boy presented with a 9 month history of intermittent dizzy spells and vomiting. Pre-operative 1.5T MRI reveals a solid/cystic enhancing tumor involving the left cerebellar tonsil. Limited ioMR showed residual tumor on T2W sequences (arrow). Resection was extended and the second ioMR shows complete resection. The 3 month follow-up scan reveals no evidence of residual/recurrent tumor on the T1 TFE post-contrast scan.

By choosing the best sequence to be performed at the start of the study, the ioMR scan can be limited to a few sequences if there is convincing evidence of residual tumor tissue. In this case the T2W image revealed residual tumor which was completely removed on re-exploration.

Pre-operative and follow-up exams on Achieva 1.5T with 8-channel SENSE Head coil. Intraoperative imaging with Achieva 3.0T and SENSE Flex-L coil.