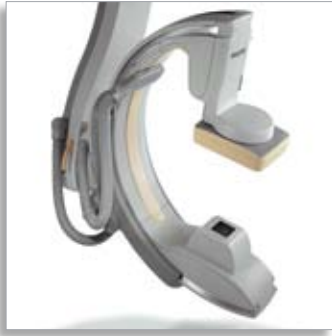



Targeting liver cancer with XperCT

Who/Where

Dr. Jeff Geschwind, Associate Professor of Radiology Surgery & Oncology, Director of Vascular & Interventional Radiology, Johns Hopkins University School of Medicine, Baltimore, MD

Challenge

Obtain enhanced visualization of cancerous lesions to facilitate more precise delivery of chemoembolization treatment

Solution

Soft tissue imaging with the Philips Allura Xper FD20, using XperCT technology, during TACE procedures

Soft tissue imaging in the angio suite delivers high spatial, high contrast resolution images before, during and after interventional procedures.

Hepatocellular carcinoma (HCC) is one of the most common and deadly types of liver tumor. For Dr. Jeff Geschwind (Johns Hopkins University School of Medicine, Baltimore, MD), trans-arterial chemoembolization (TACE) is a logical, palliative treatment option for non-resectable HCC.

“We know that only 10 to 20% of liver cancer patients are eligible for surgical intervention, either resection or transplant,” says Geschwind. “For 80 to 90% of HCC cases, interventional radiology is really the only option.”

Visualization is the key

Successful chemoembolization depends upon the interventional oncologist’s ability to deliver chemotherapeutic agents and anti-angiogenesis compounds through the hepatic artery and small vessels, directly to the tumor.

Dr. Geschwind uses the Philips Allura Xper FD20 interventional angio suite for all of his TACE procedures. “In the angio suite we perform a diagnostic angiogram to delineate the anatomy and identify the tumors. We advance the catheter into the vessel that directly supplies blood flow to the tumor. Once we are in close proximity to the tumor itself, we deliver localized, high doses of chemotherapy.”



Dr. Jeff Geschwind, Johns Hopkins University School of Medicine

To determine the proper position for access to the tumor, Dr. Geschwind uses a frontal AP projection (with contrast) for good correlation to pre-treatment Contrast Enhanced (CE)-MRI or CT scan. Reading the “tumor blush” from this direction however can be misleading. Overlapping tumors or feeder vessels may be difficult to delineate.

PHILIPS

“With the introduction of XperCT into the angio suite, it is now very easy to perform an XperCT scan before or during the procedure in order to ensure that the tumors are precisely targeted.”

“Although in the majority of instances we would be very satisfied with the end result,” says Geschwind, “there were times where we would miss the tumor or not treat it completely.”

Philips XperCT soft tissue imaging

CT is generally regarded as capable of providing exceptional soft tissue and bone structure imaging – the best information for the safest approach in an interventional procedure. Yet once a patient is in the angio suite, access to a CT scanner can be problematic.

With the XperCT feature of the Philips angio suite, acquisition of CT-like images is possible within the interventional lab. Improvements in planning, guidance and evaluation can be accomplished while the patient is on the table.

XperCT reconstructs 3D volumes from rotational fluoroscopy acquisitions. The acquired images (with or without contrast)

are automatically reconstructed into an isotropic soft-tissue volume, which can be viewed and manipulated both in the control room as well as tableside, in the examination room.

Increased confidence

At Johns Hopkins, Dr. Geschwind has discovered that XperCT gives him the edge he needs to be certain the chemoembolization mixture is delivered accurately during TACE procedures. “With the introduction of XperCT into the angio suite, it is now very easy to perform an XperCT scan before or during the procedure in order to ensure that the tumors are precisely targeted. Then if needed, we can adjust the catheter position before delivering the chemotherapy.”

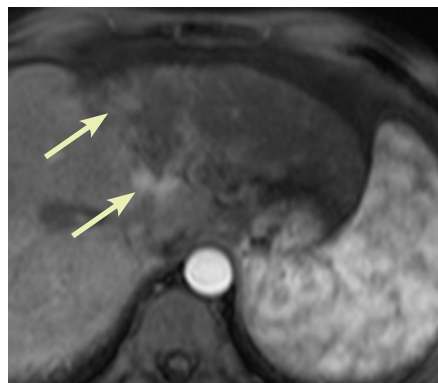
He continues, “In fact, we may use XperCT three times – before administration of the chemoembolization mixture, during the procedure to ensure we’ve done it correctly, and again at the end to confirm that we got everything right.”

Case study

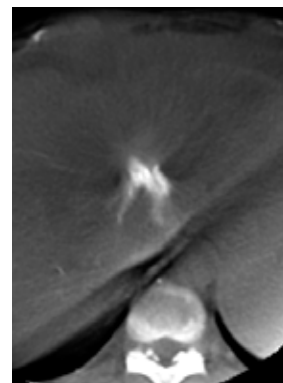
When a 49 year-old woman with liver metastasis of adenocarcinoma with an unknown primary was scheduled for TACE, Dr. Geschwind turned to XperCT to clarify the process.

Using a CE-MRI scan taken three days prior as reference, Dr. Geschwind performed a traditional DSA that showed a “classic hepatic vascular anatomy with a patent portal vein.” Following this pathway, he introduced his catheter into the left hepatic artery and on to the tumor.

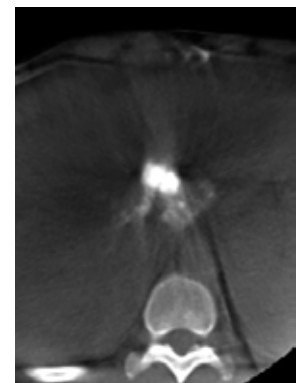
A CE-XperCT scan was completed to verify the treatment location. Interestingly, this enhancement showed only the middle portion of the tumor served by the artery accessed. The decision was made to release half of the drug and reserve the rest. A plain post-chemoembolization XperCT scan confirmed the initial success of this portion of treatment.



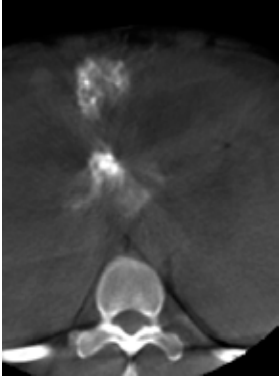
CE-MRI (3 days before TACE)



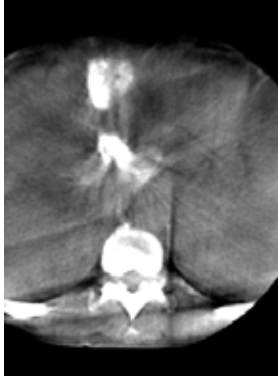CE-XperCT scan (verification before treatment)



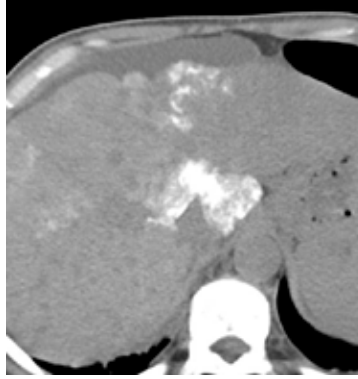
Plain post-chemo XperCT scan after half treatment



CE-XperCT scan (verification before 2nd treatment)



Plain post-chemo XperCT scan after all treatment

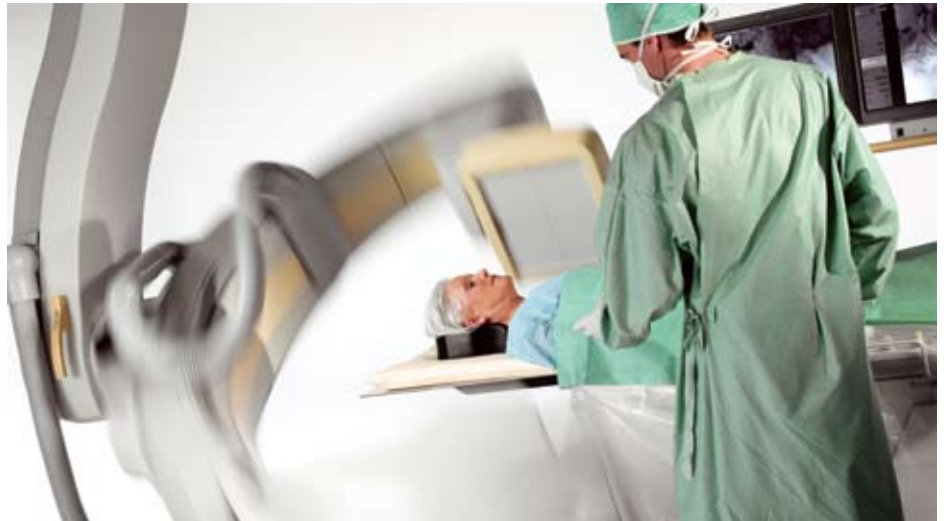

CT scan on the next day

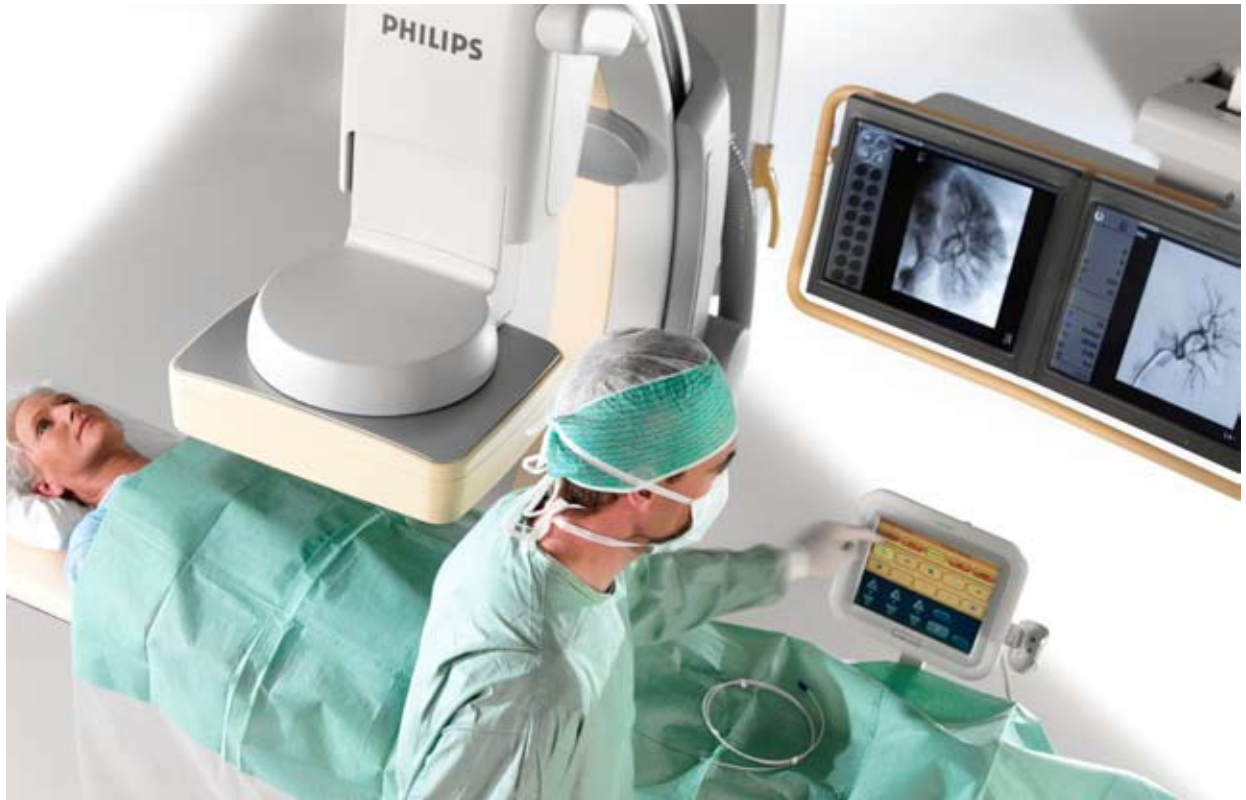A second DSA was then performed to identify the blood supply to the anterior lesion that had been missed. With the catheter advanced into a different arterial branch, another CE-XperCT scan was done to verify this new position. Again, the image provided interesting insight. Enhancement here showed a vessel branch causing leakage of contrast material into the stomach. So the catheter was advanced past the branch and the remainder of the chemoembolization mixture slowly released into the tumor to avoid reflux into the stomach. A final plain post-chemoembolization XperCT scan confirmed the success of this second portion of the procedure.

The next day, upon review, Dr. Geschwind could see the strong correlation between the XperCT scans taken during the procedure and the post-TACE CT. All showed a successful outcome.

“Without XperCT,” says Geschwind, “we would not have been able to correct the issues we encountered, because with DSA we were convinced we were in the right place. That’s a thrilling example of the usefulness of XperCT.”



“Without XperCT we would not have been able to correct the issues we encountered.”



Enhanced patient care

XperCT gives Dr. Geschwind instant feedback during his procedures. This allows him to adjust his treatment as necessary. Without XperCT, any problems that arise would have to be addressed at a later time – often weeks later.

“In the past we used to rely exclusively on the post TACE CT that was performed the next day to confirm our results. We don’t any more. Now we rely on XperCT. So, instead of waiting for a 24-hour period for confirmation that what we did was successful, we have the results immediately. I can tell that we have targeted the lesions properly, that there is adequate distribution and that everything is correct. That’s an amazing time-saving element for me, and helps us to provide exceptional service for our patients.”

A critical tool

XperCT is an important part of how Dr. Geschwind approaches each procedure. “Using it is now a matter of course,” he says.

And he has his eye to the future. “There are other things we hope to do with XperCT images, like combining chemoembolization with an R/F ablation procedure where we use a needle that expands into the tumor to burn it immediately after chemoembolization.”

“I consider XperCT a revolutionary technique because it allows us to treat patients more precisely. As a result, XperCT may become indispensable for virtually all oncology procedures and perhaps most types of embolization procedures, as well.”



© 2006 Koninklijke Philips Electronics N.V.
All rights are reserved.

Philips Medical Systems Nederland B.V. reserves the right to make changes in specifications and/or to discontinue any product at any time without notice or obligation and will not be liable for any consequences resulting from the use of this publication.

Philips Medical Systems is part of Royal Philips Electronics

www.medical.philips.com
medical@philips.com
fax: +31 40 27 64 887

Printed in the USA
4522 962 19221/722 * OCT 2006

Philips Medical Systems
Global Information Center
P.O. Box 1286
5602 BG Eindhoven
The Netherlands